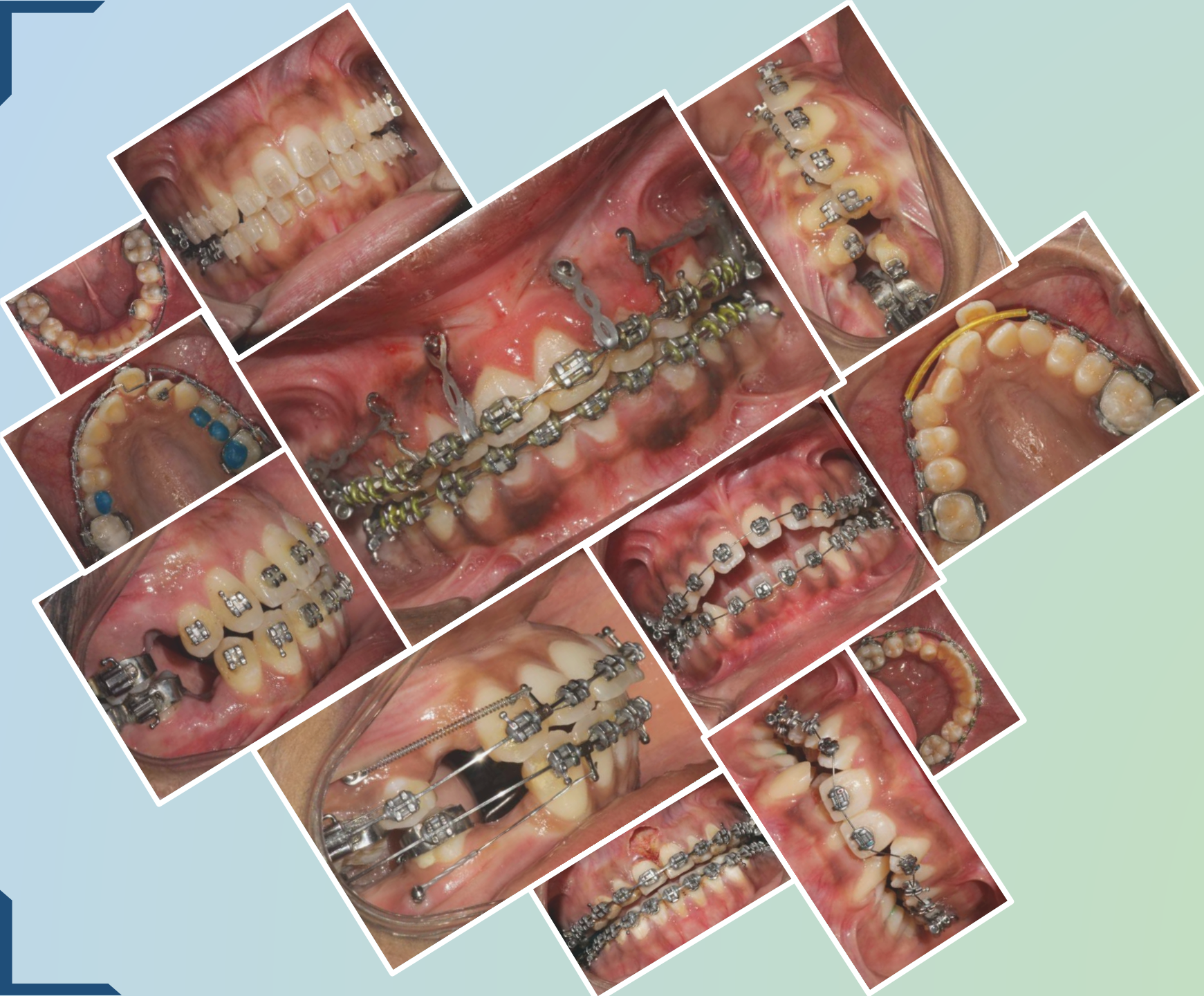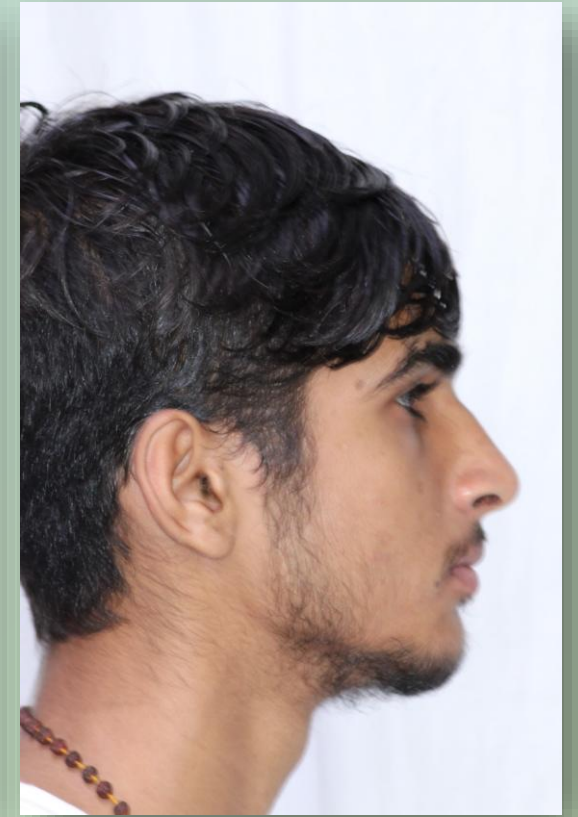



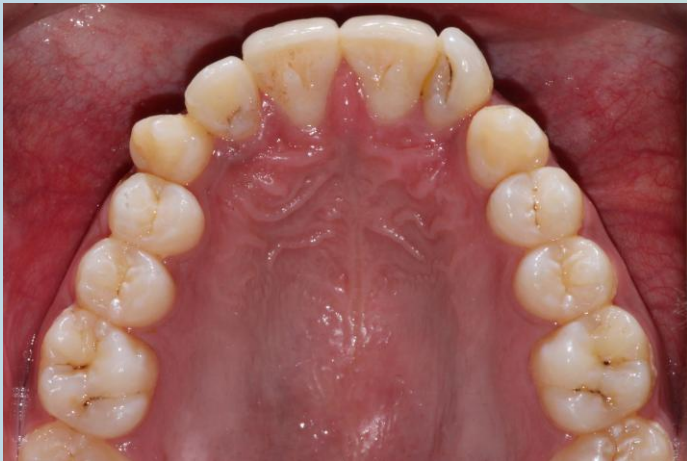
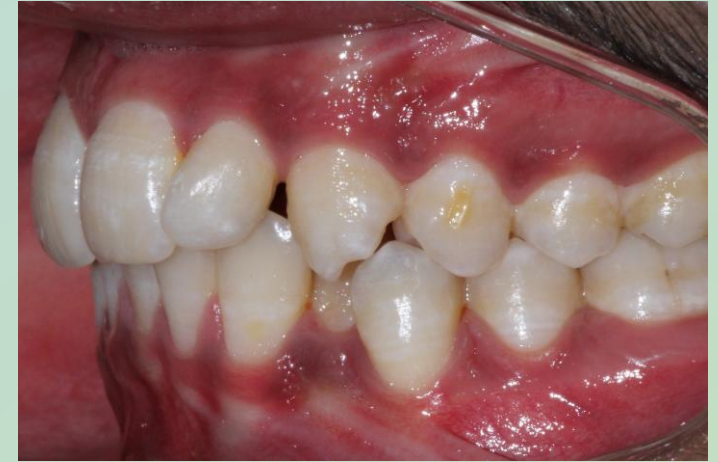
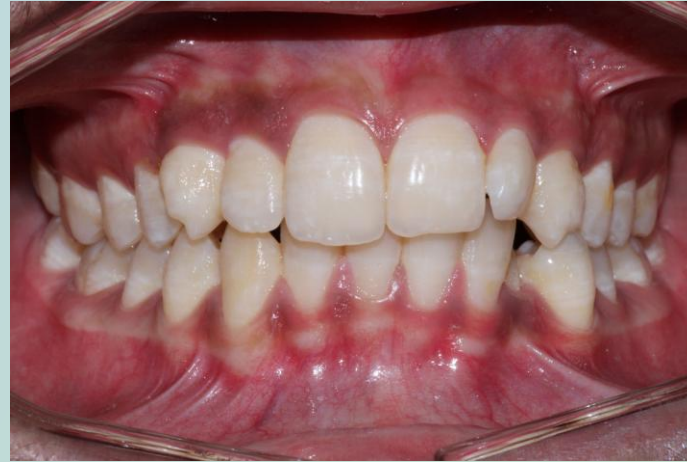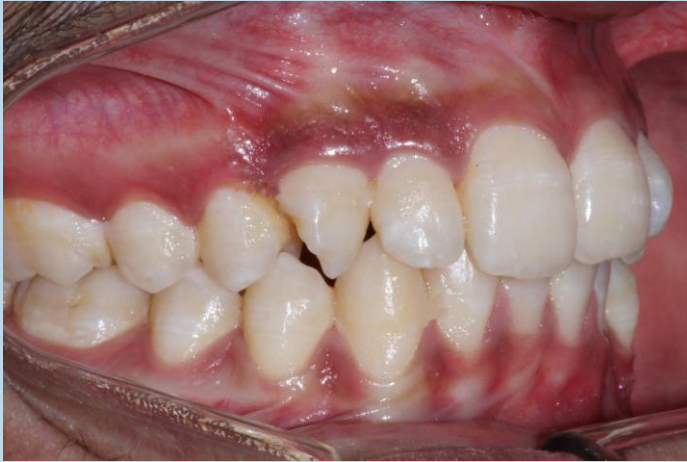Clinical Album

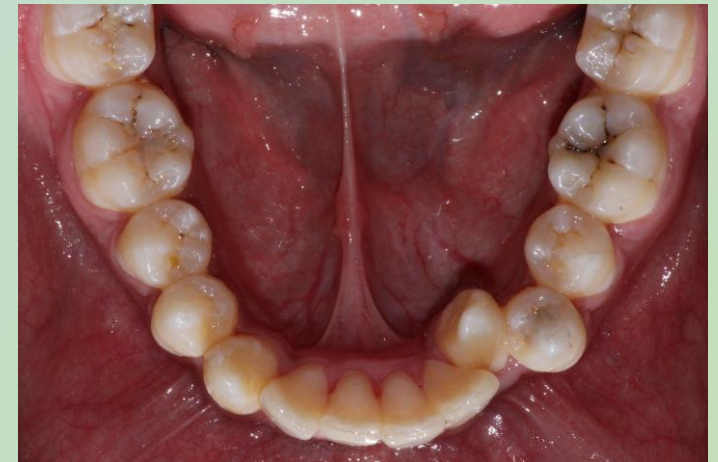*Piggy Back Mechanics - correction of linguallly
erupted canine*

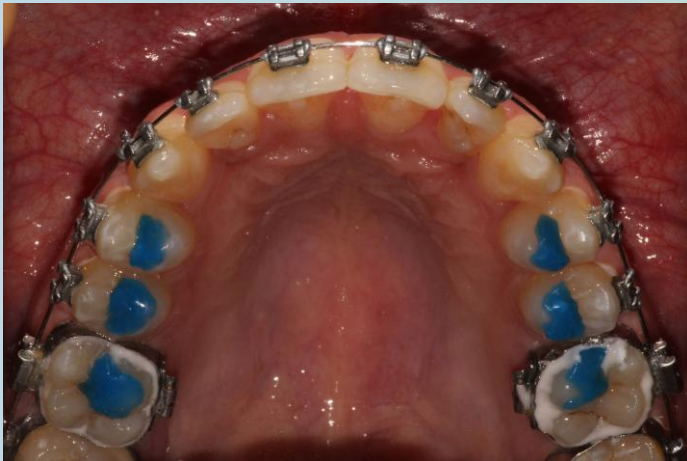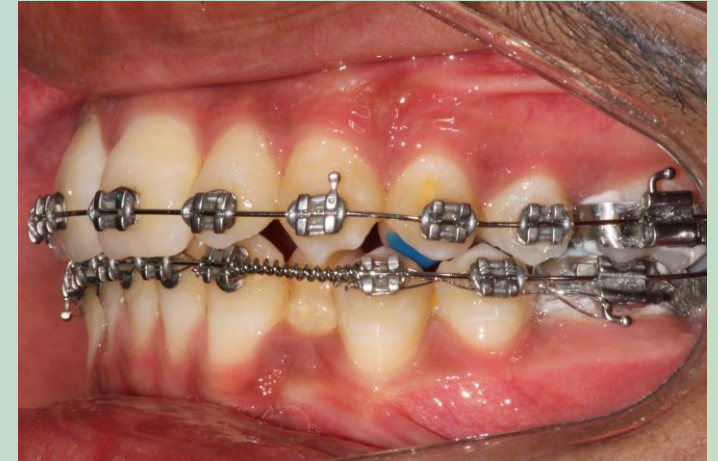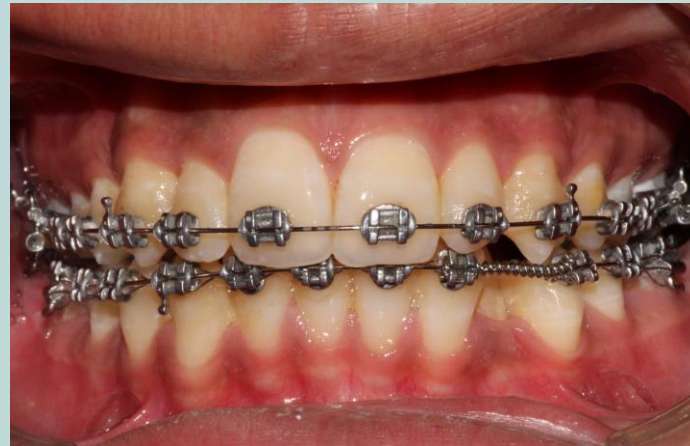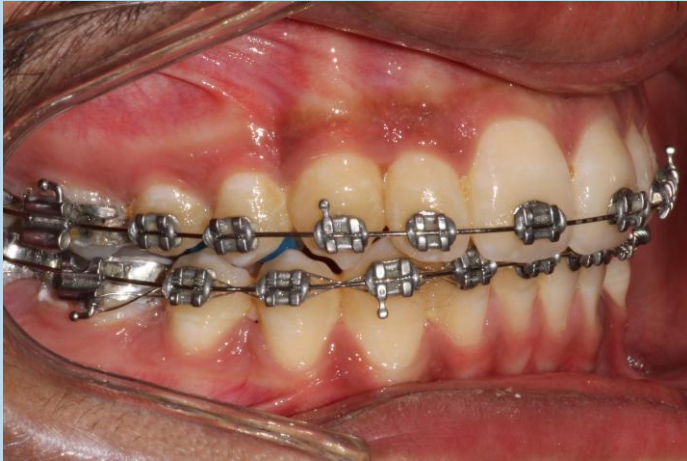


Pre - treatment Extraoral Photographs

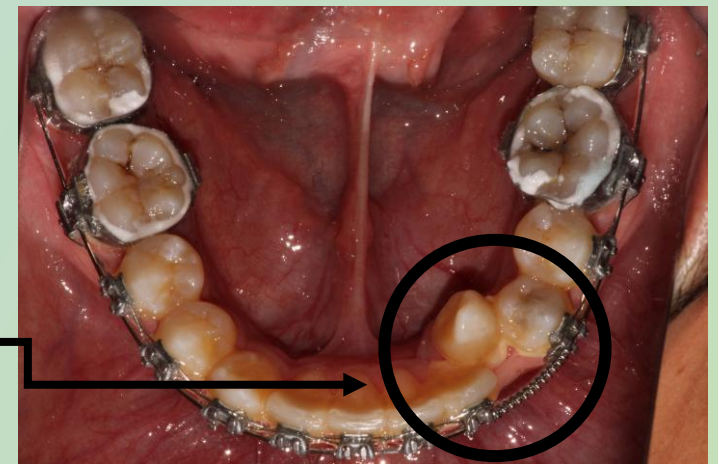


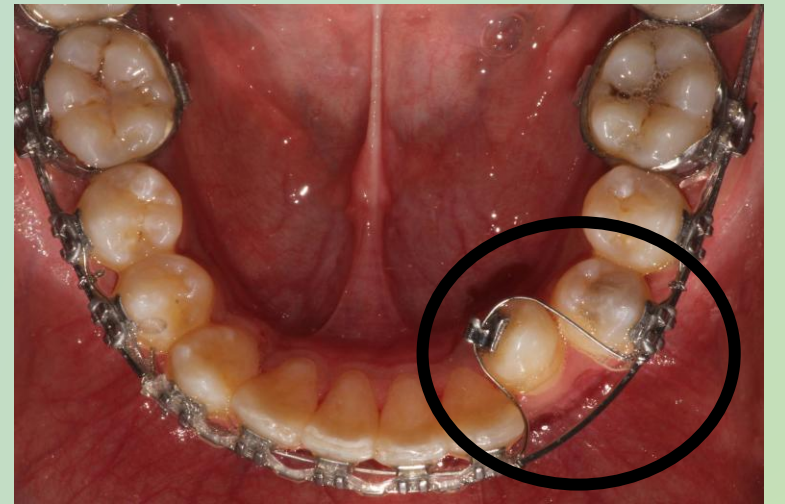
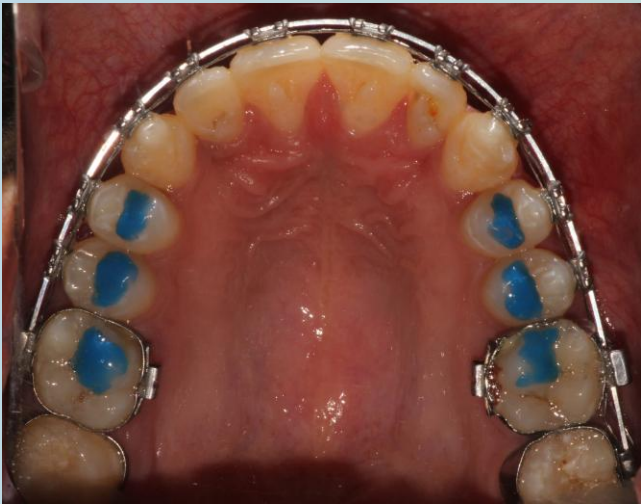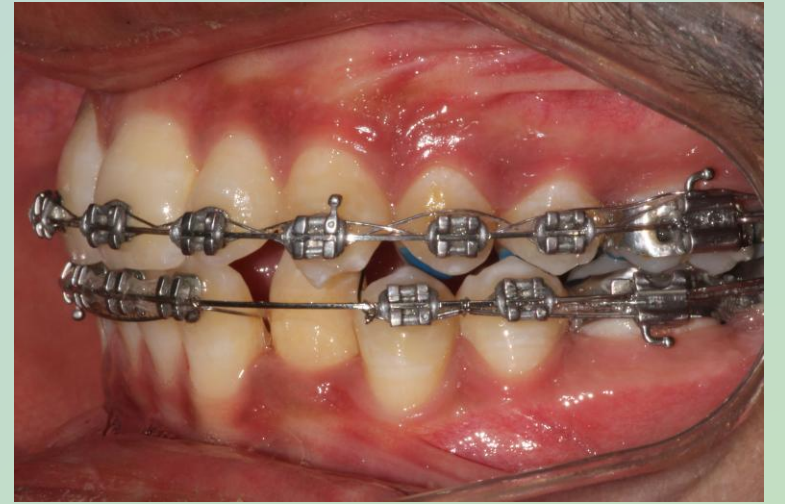
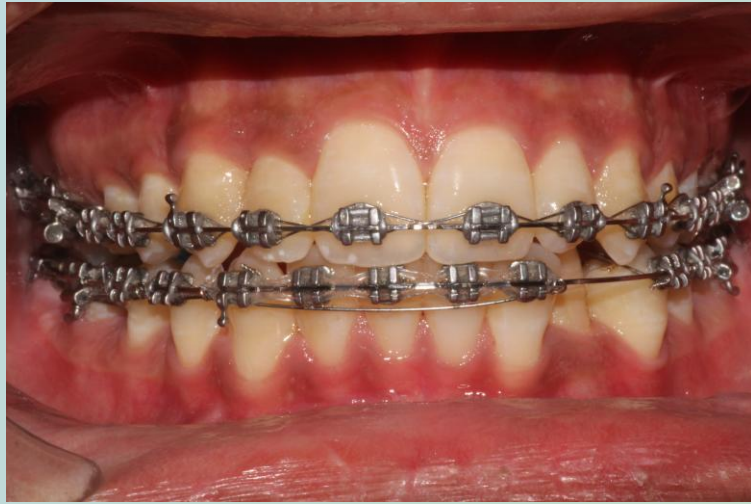
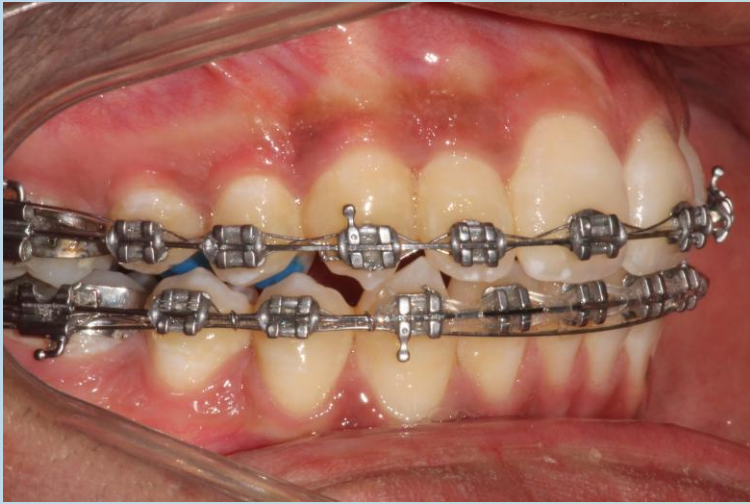
Pre - treatment Intraoral
Photographs





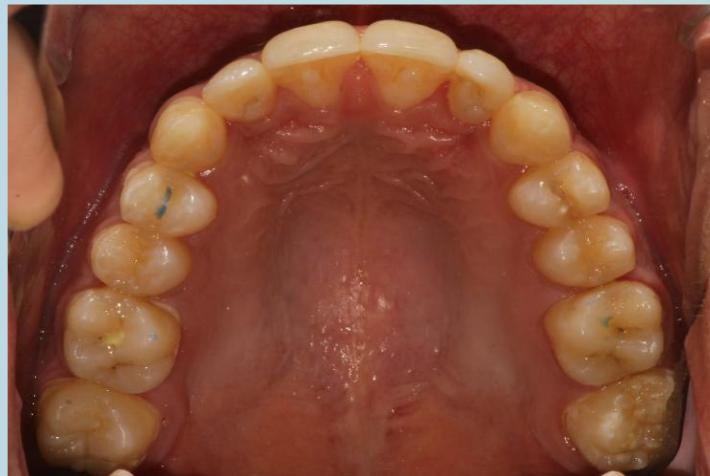
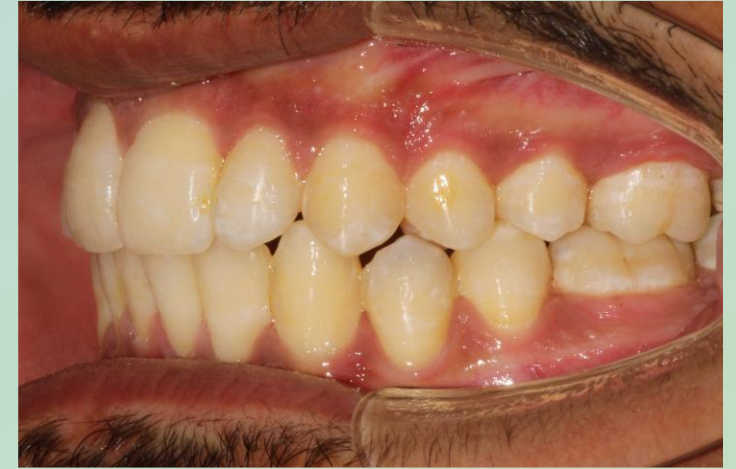
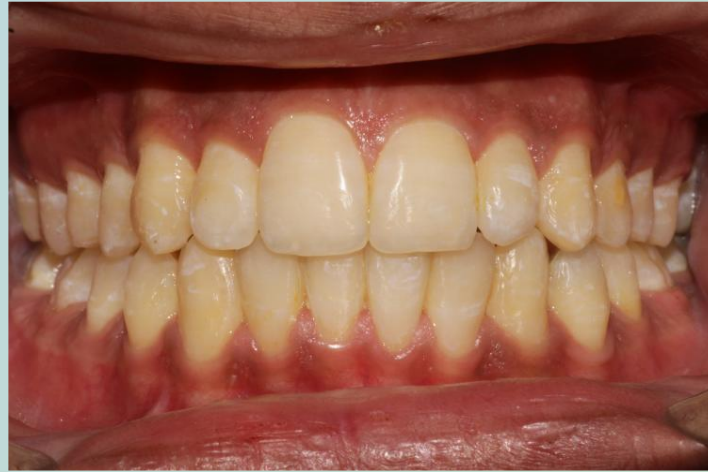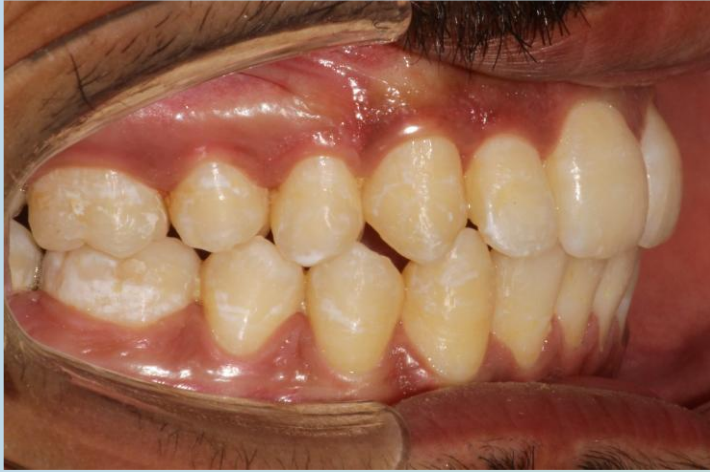Space creation done using
open coil spring between 32
and 34



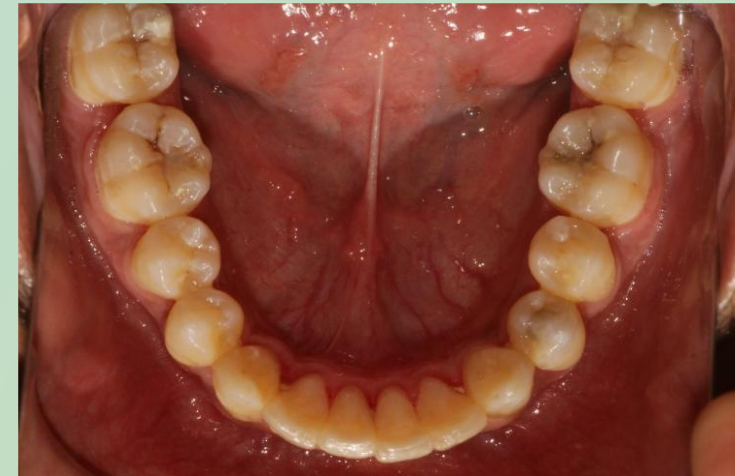




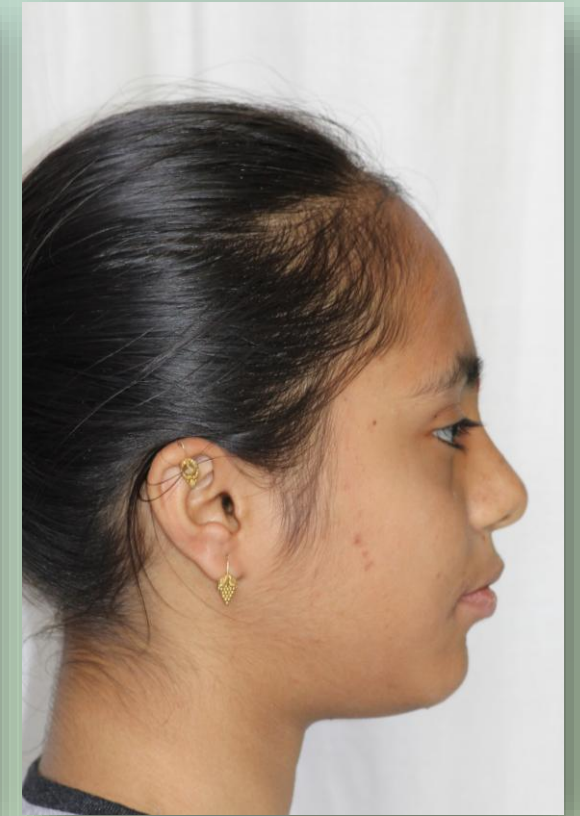Post Treatment Extraoral Photographs



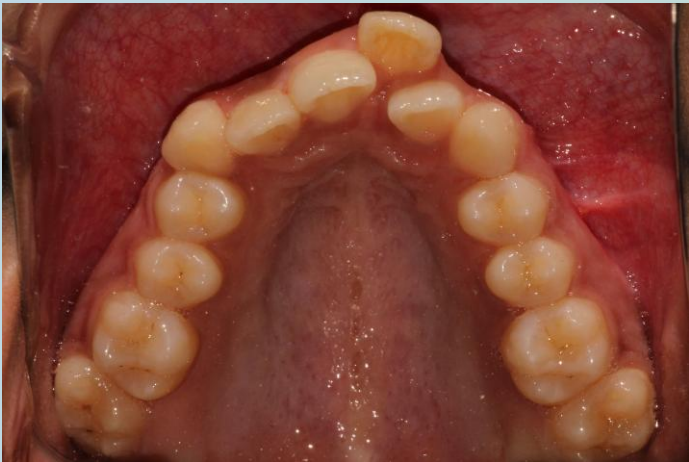
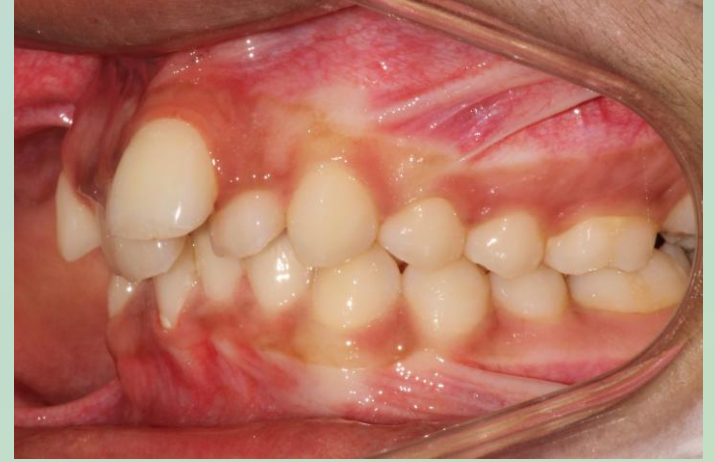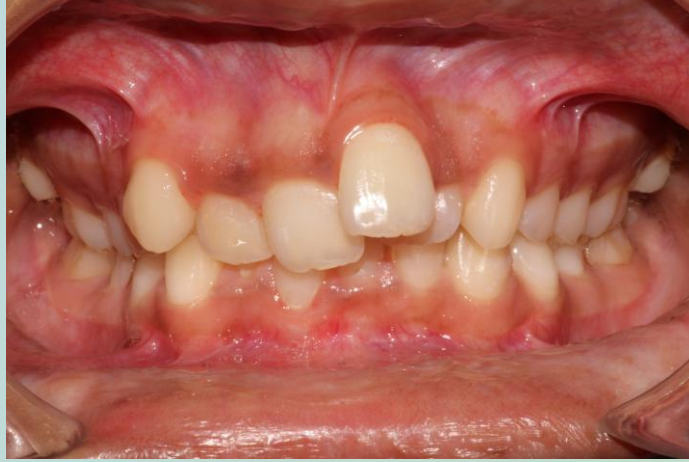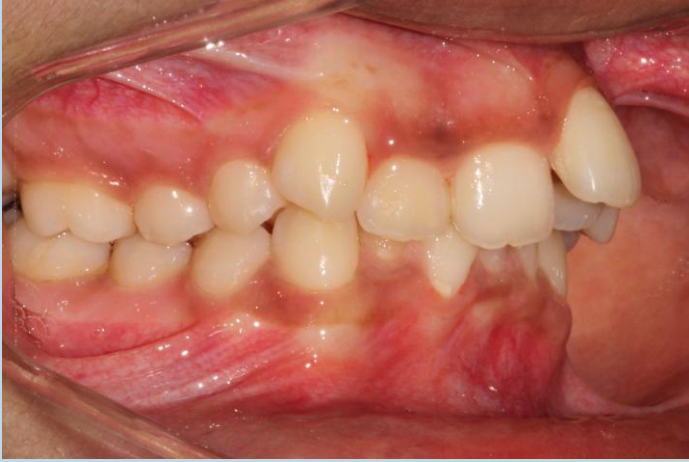Post Treatment Intraoral
Photographs



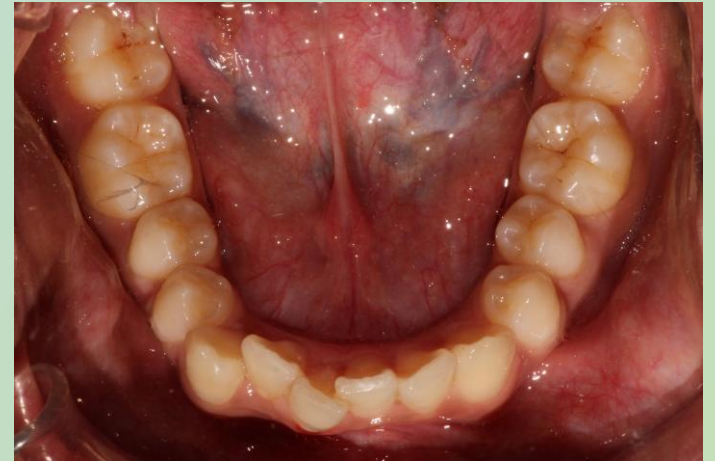*Sequential Bonding and Piggy back mechanics –
Severe crowding*

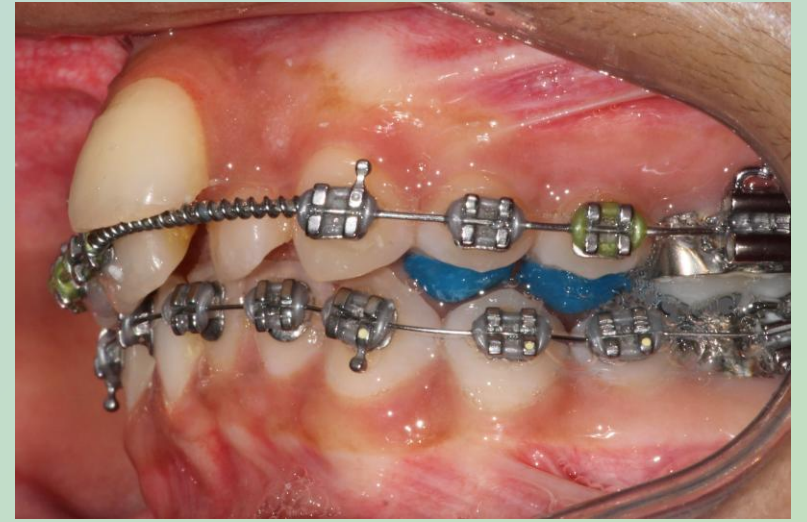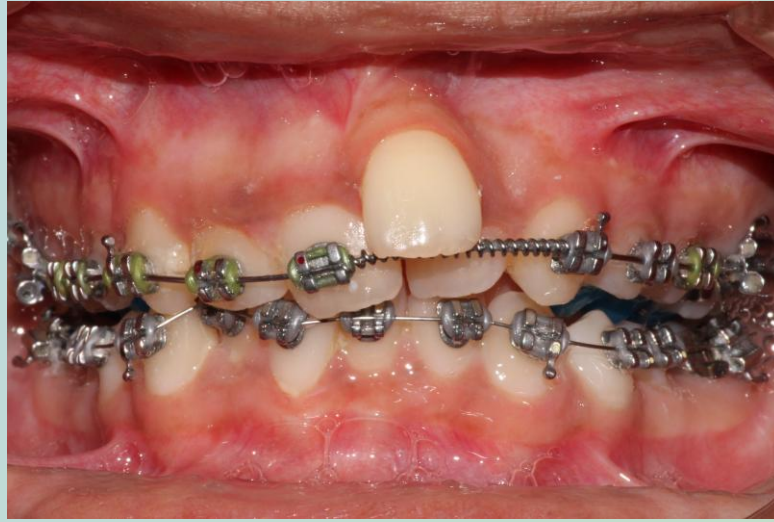
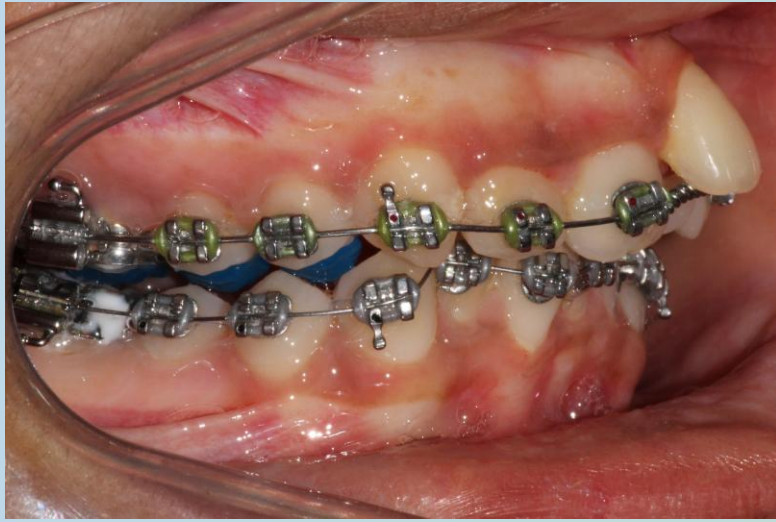


Pre - treatment Extraoral Photographs

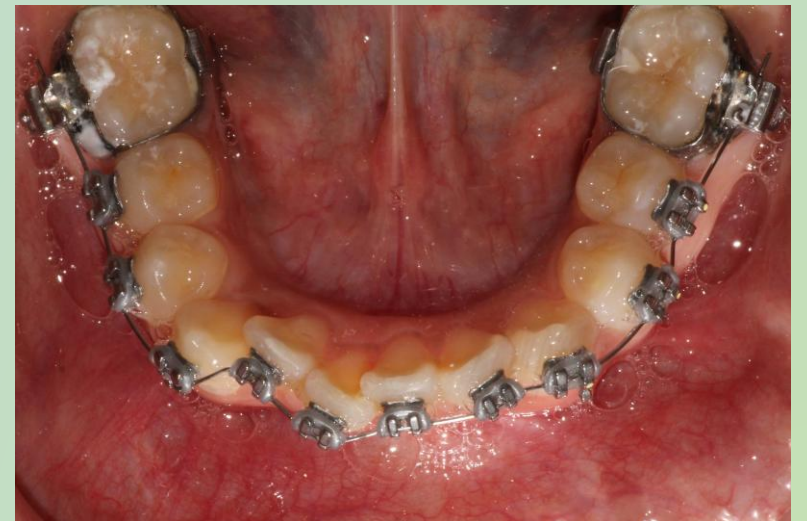
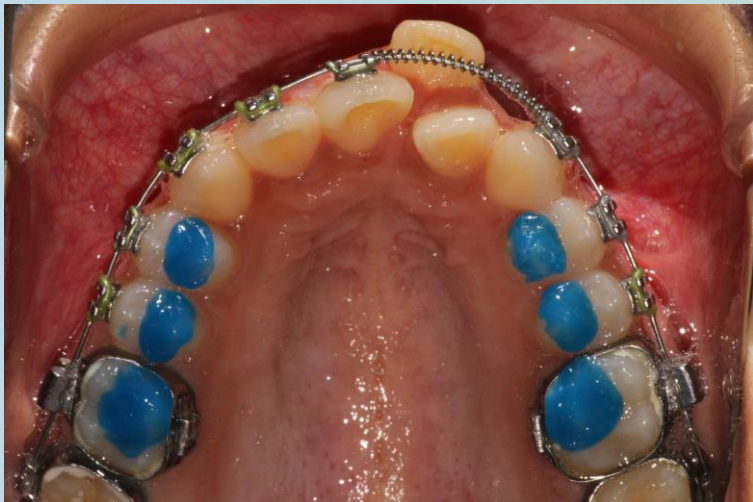
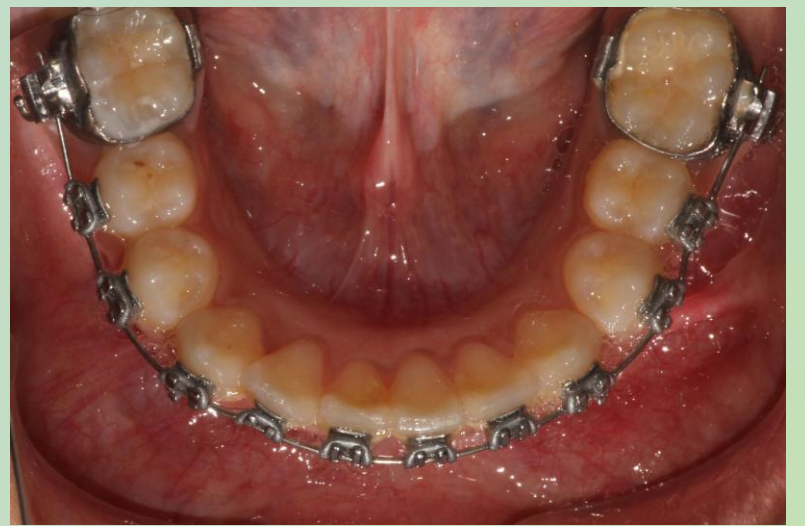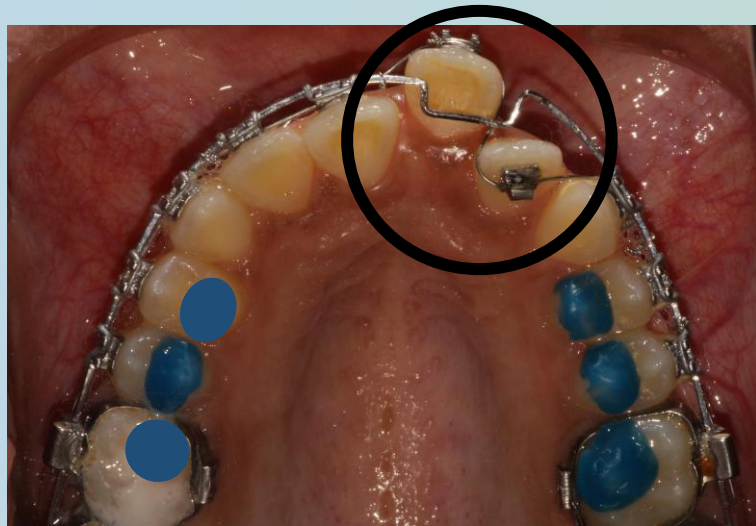
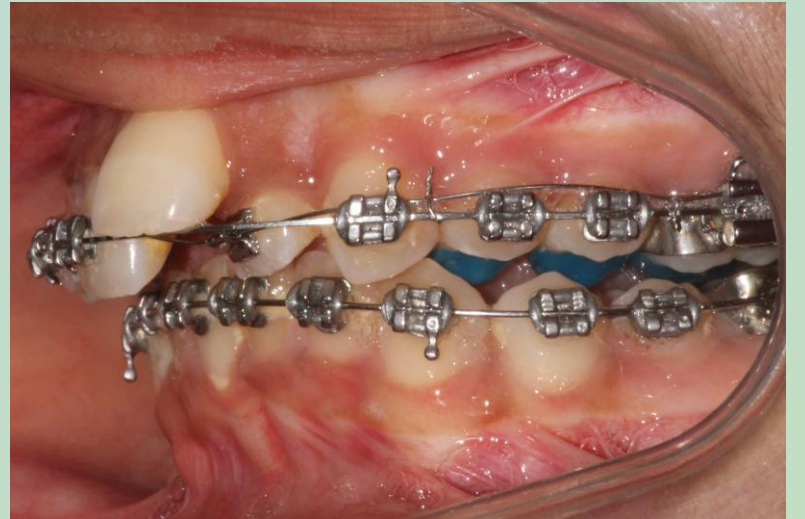
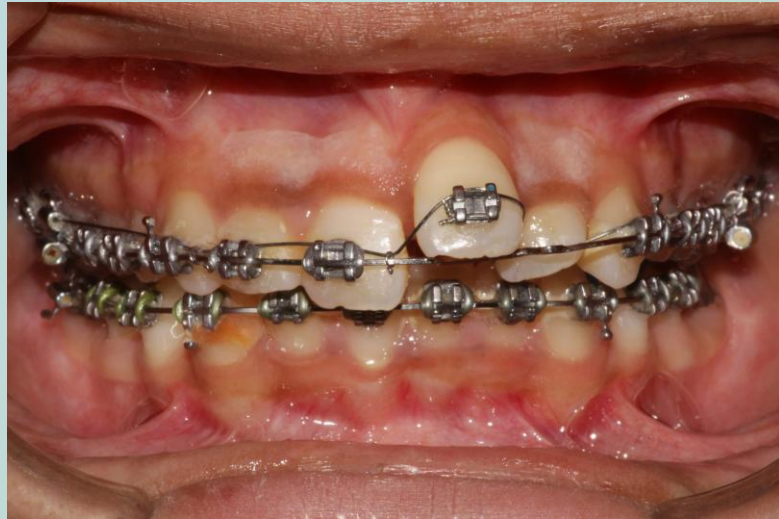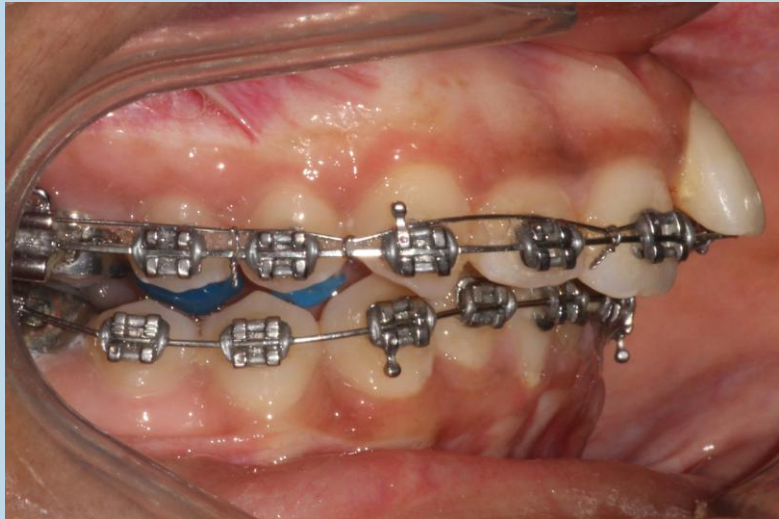
Pre - treatment Intraoral
Photographs

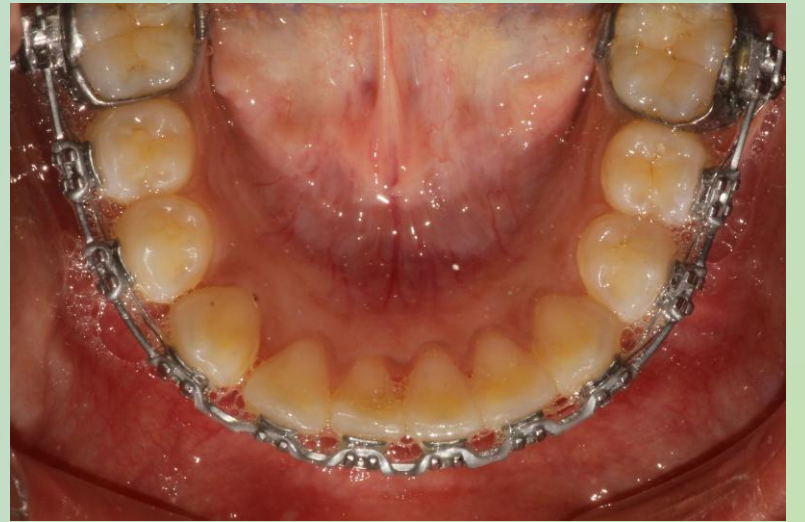
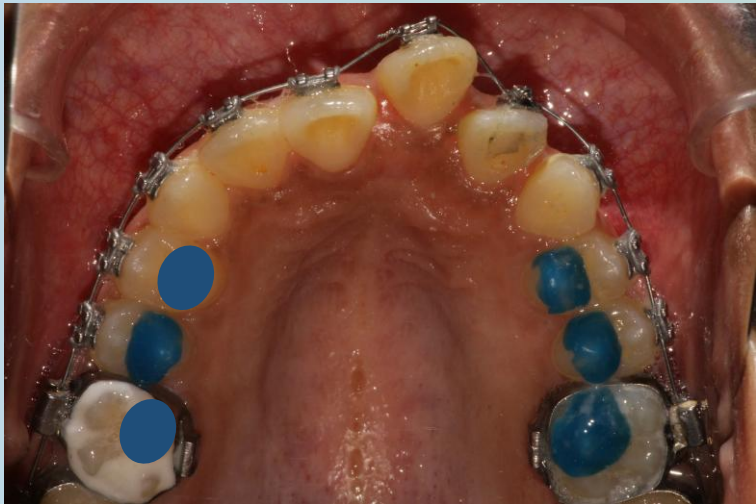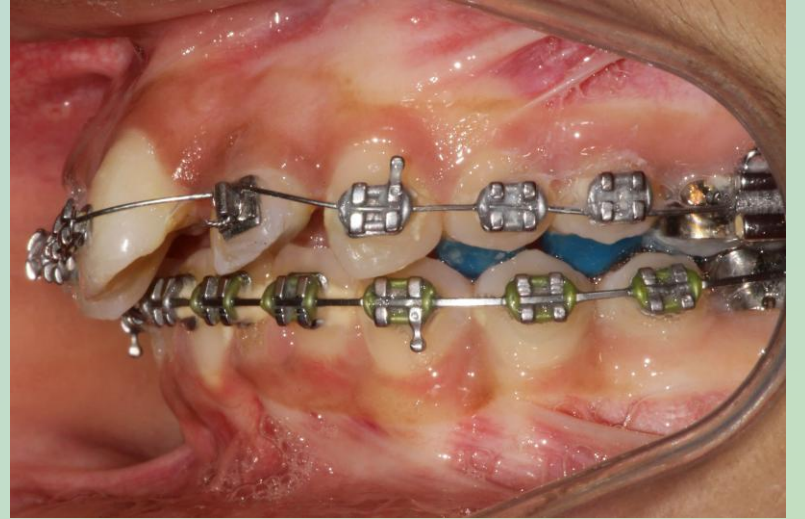
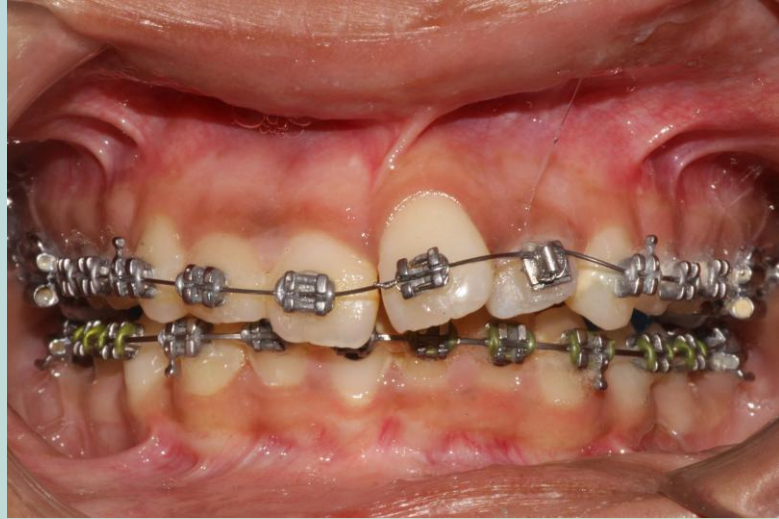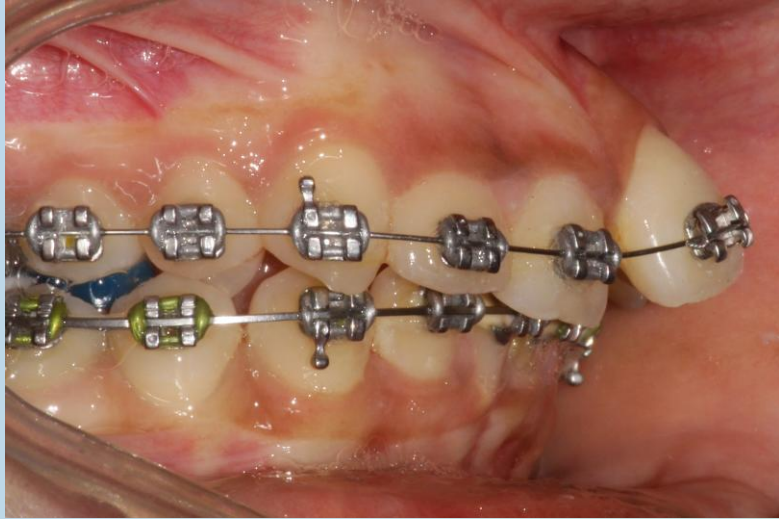




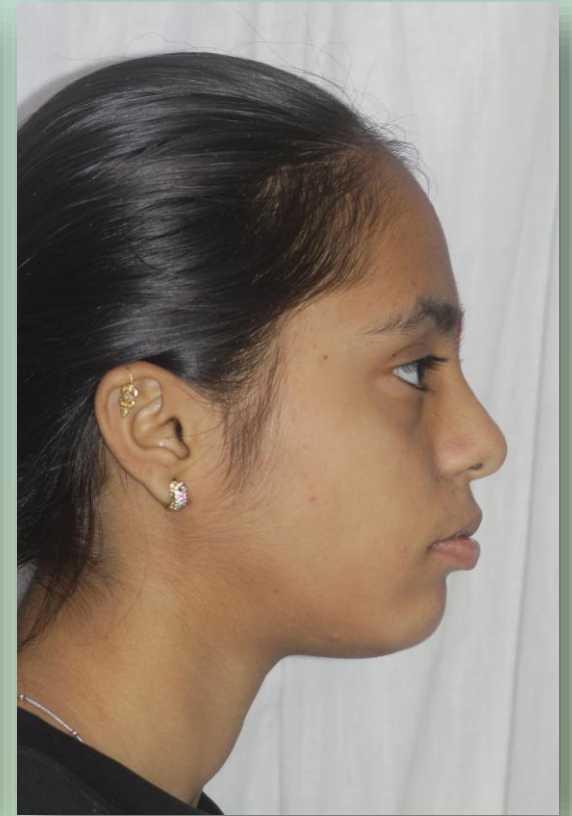
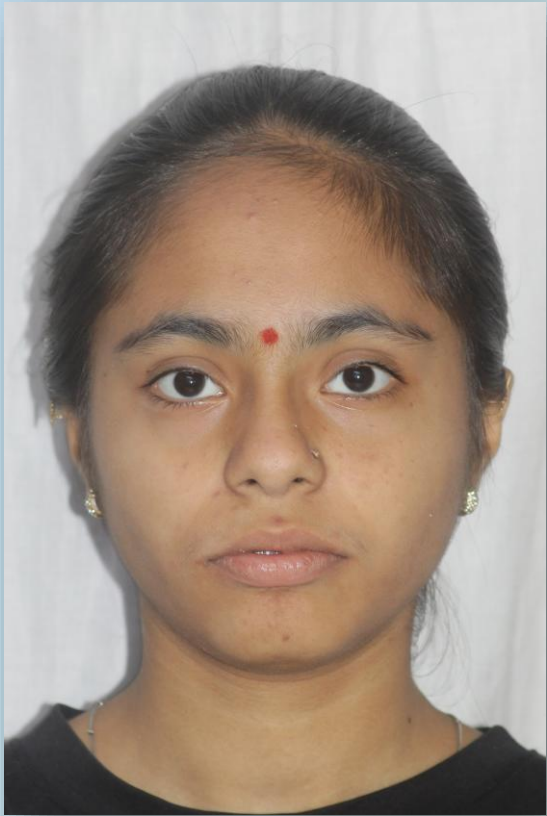Sequential Bonding plus
incorporation of open coil
spring in maxillary anterior
region to gain space for 21 and
22

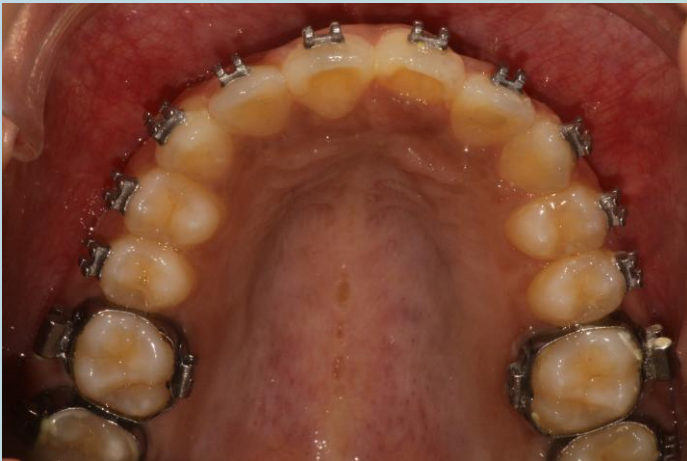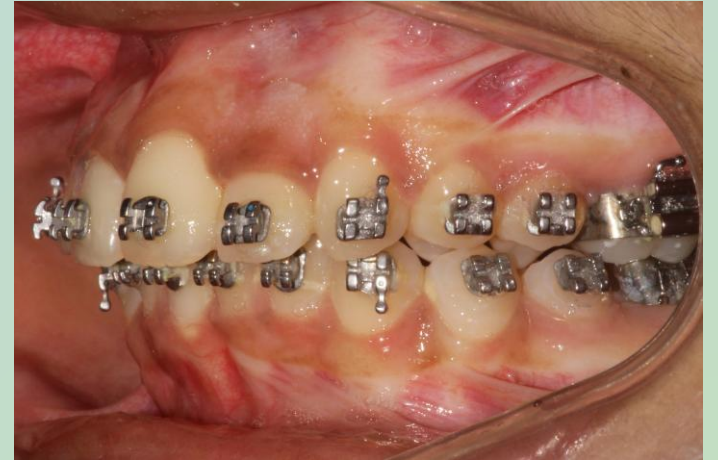

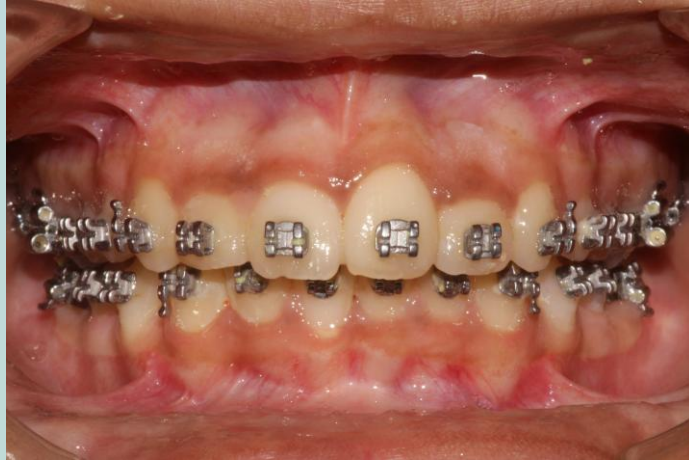
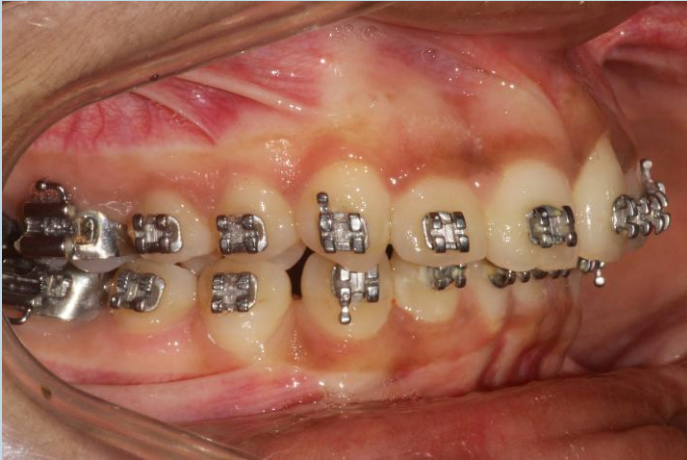

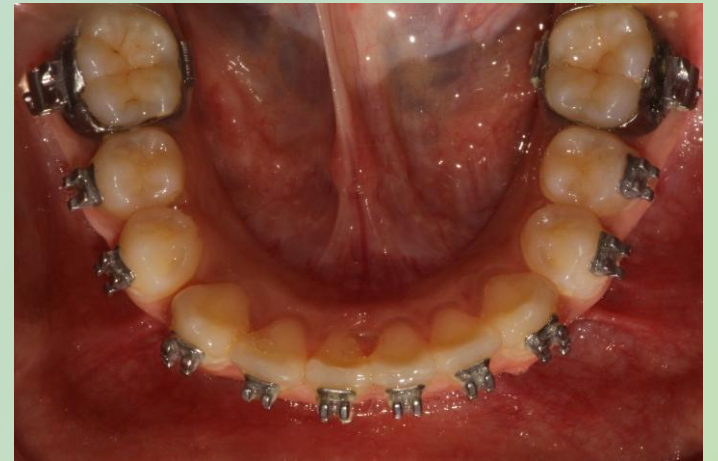





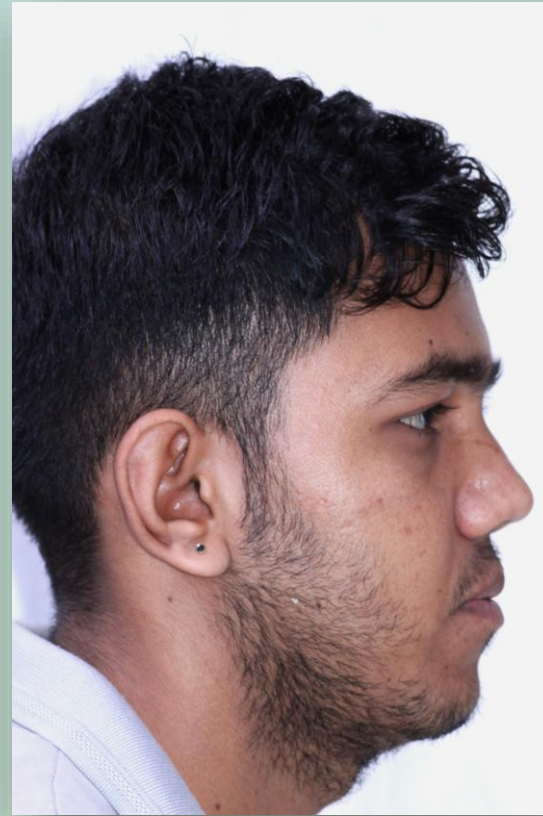
Current Status Extraoral Photographs



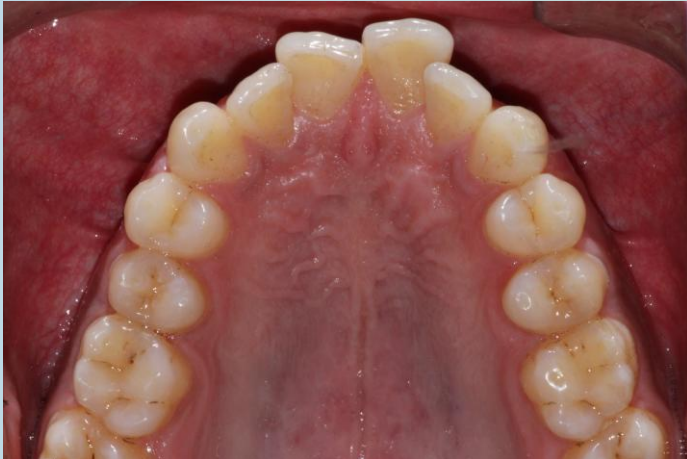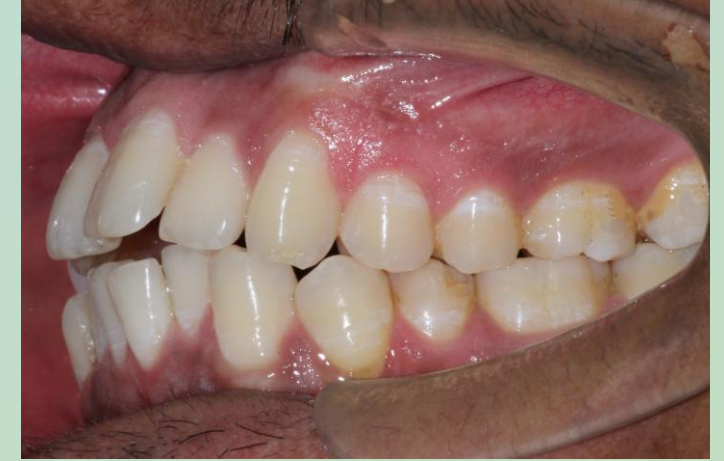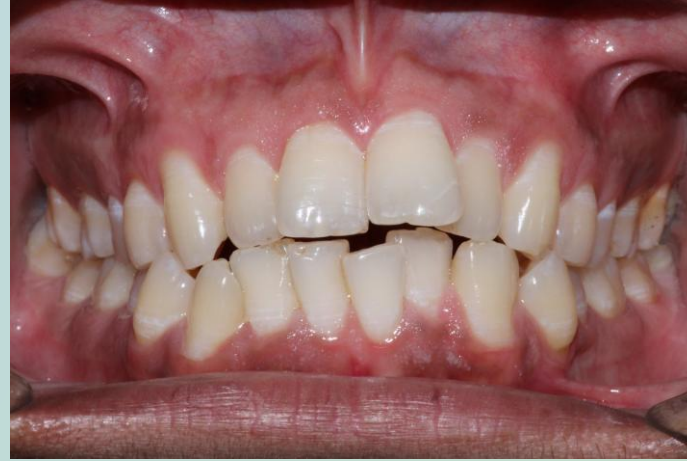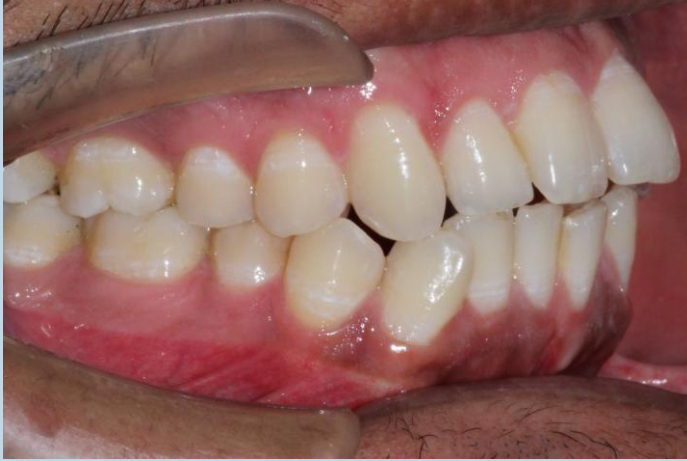Current Status Intraoral
Photographs



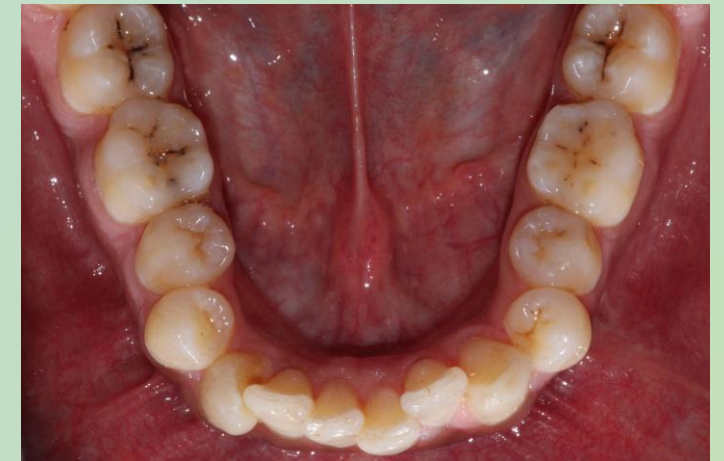*Symmetric extraction of all four second premolars in
dental open bite case*

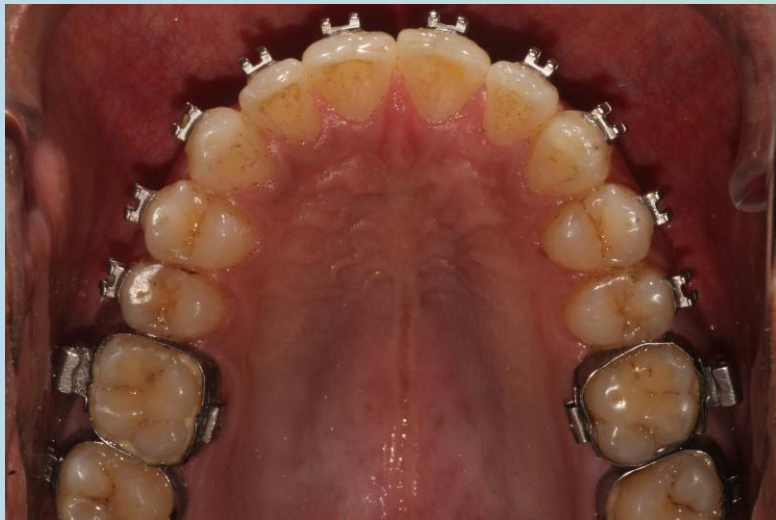
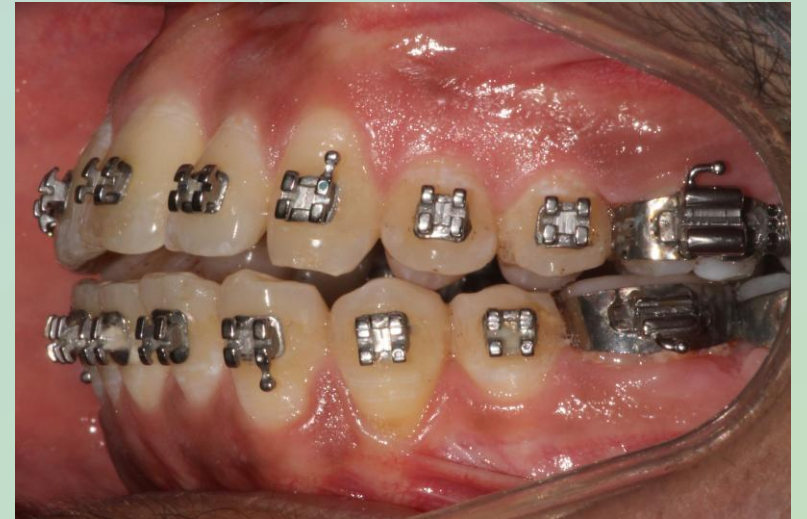
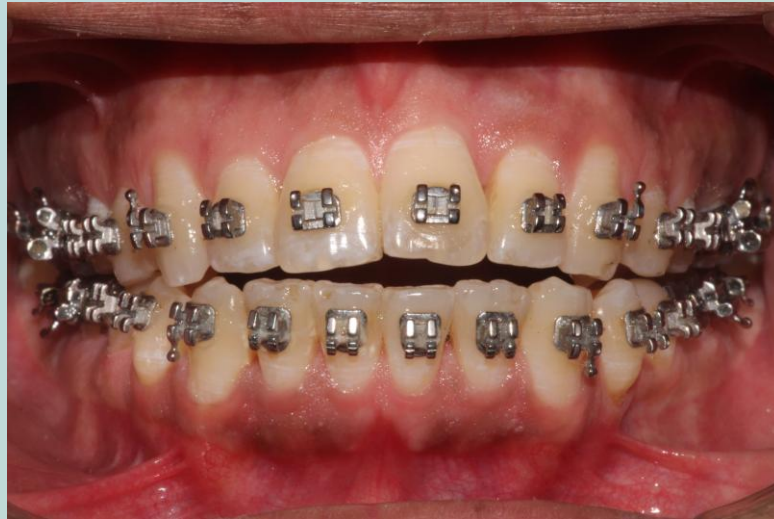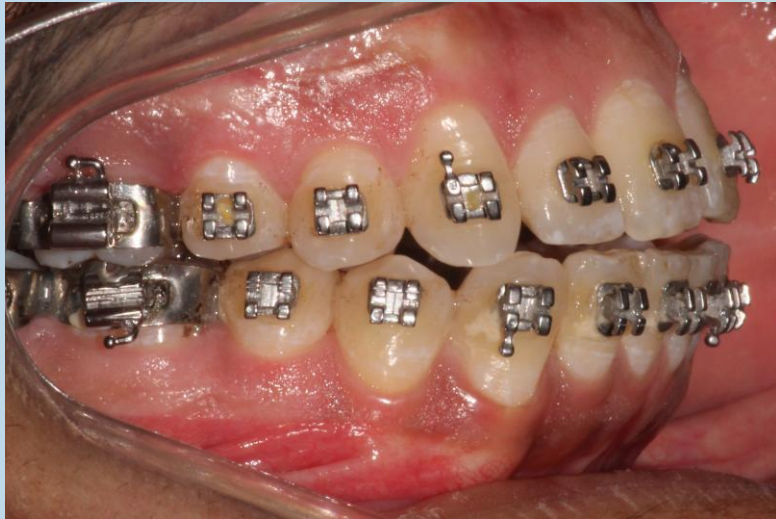Pre - treatment Extraoral Photographs

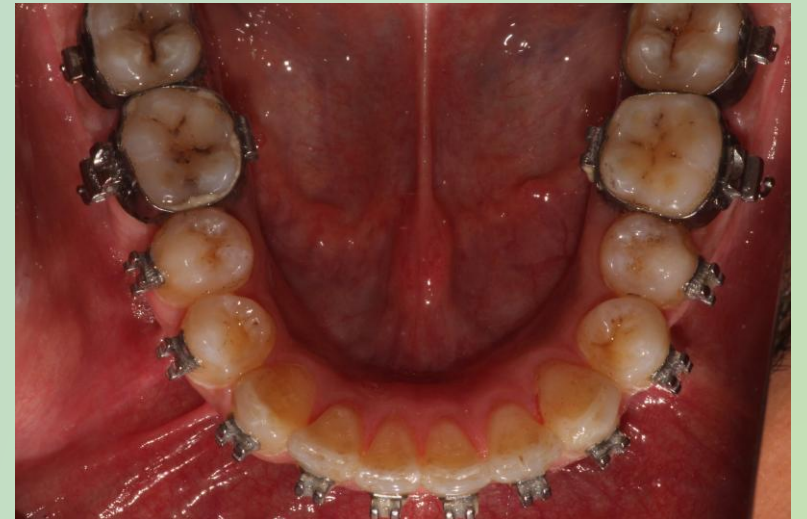


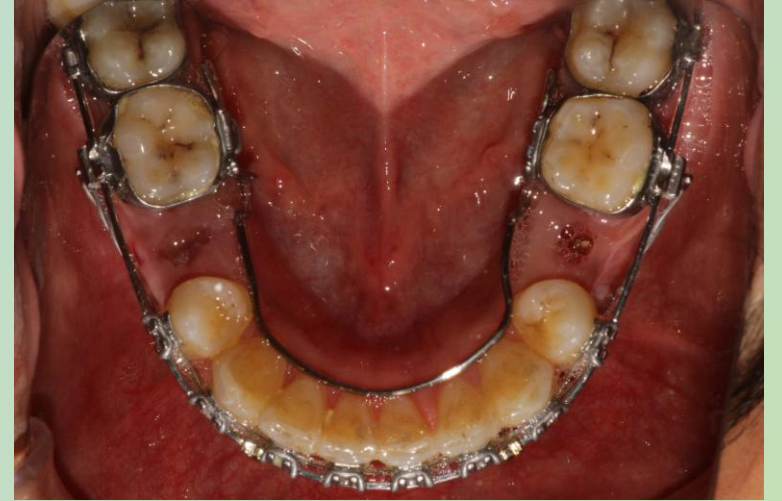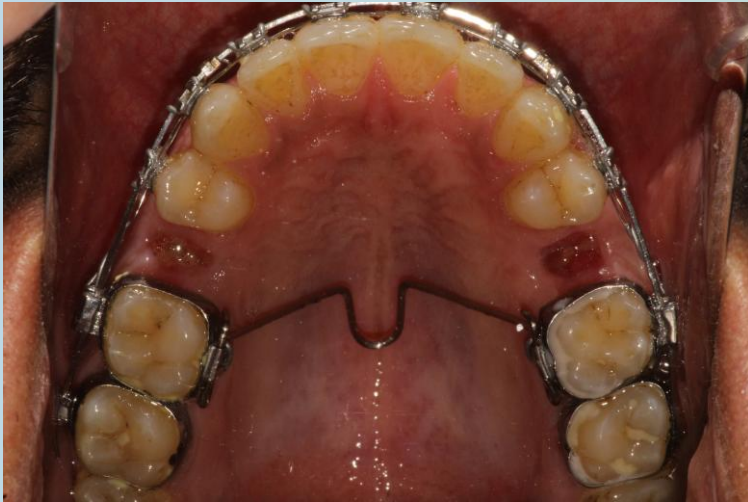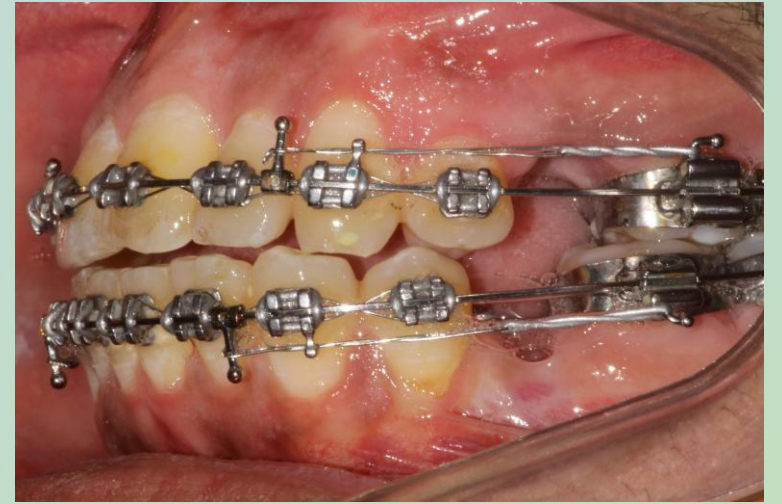
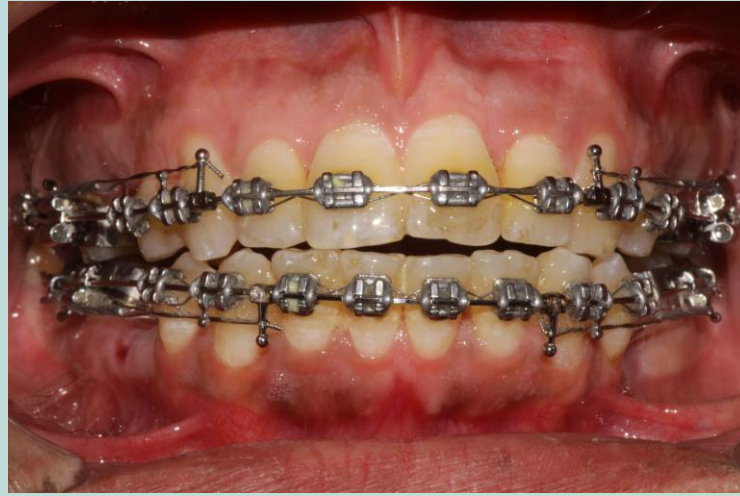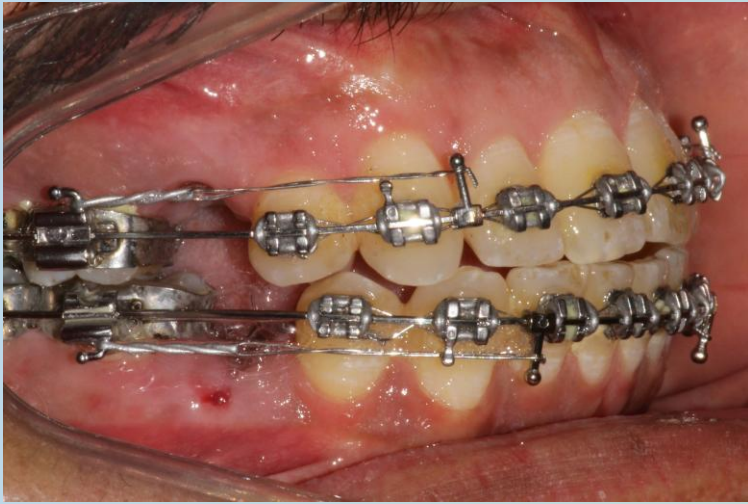
Pre - treatment Intraoral
Photographs





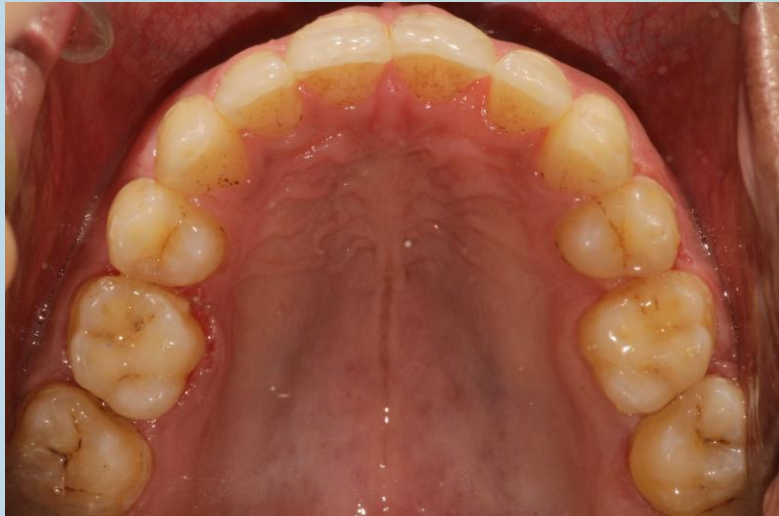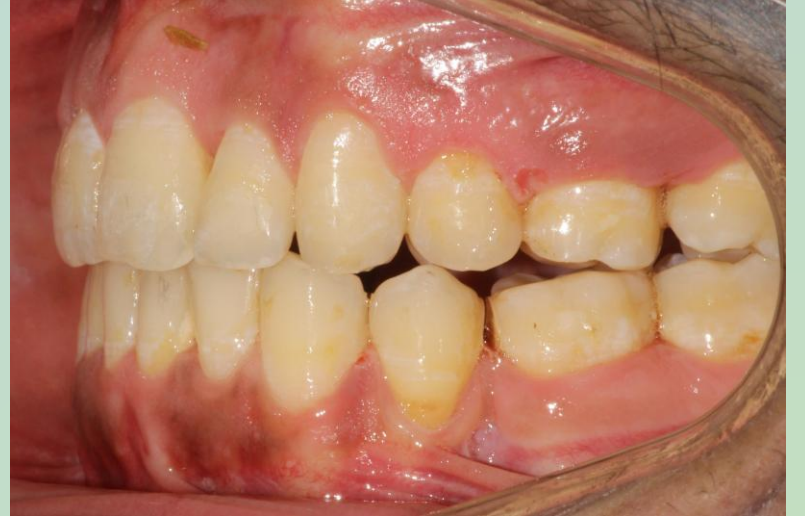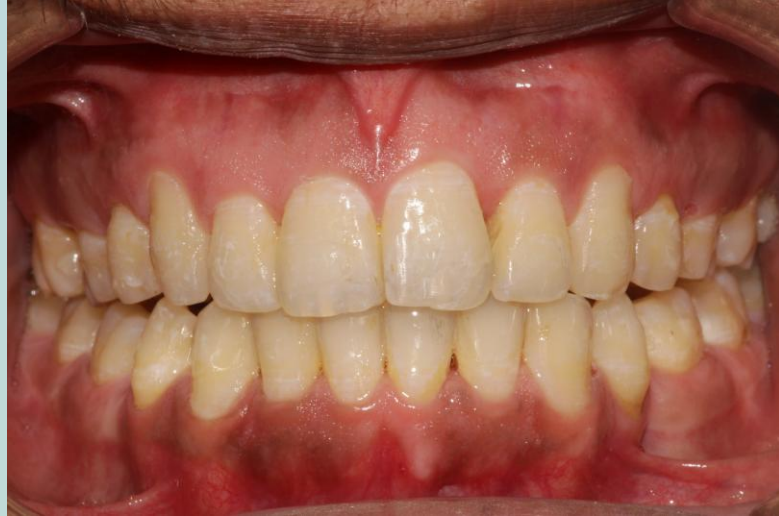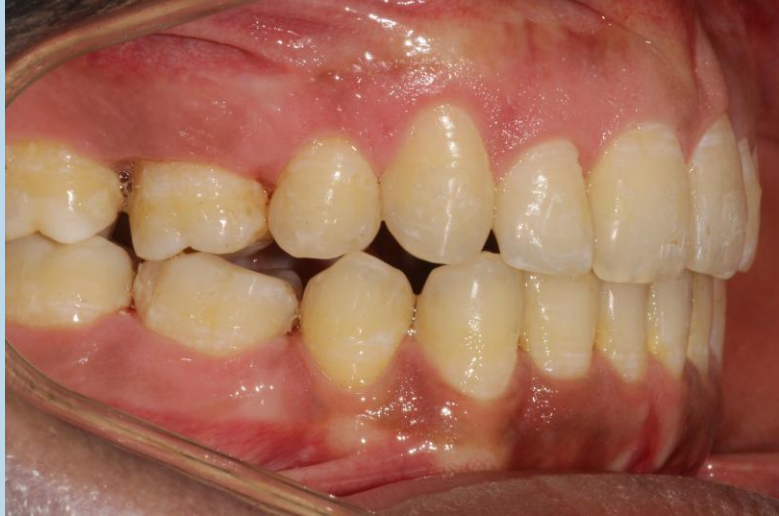Leveling and Aligning
Intraoral Photographs



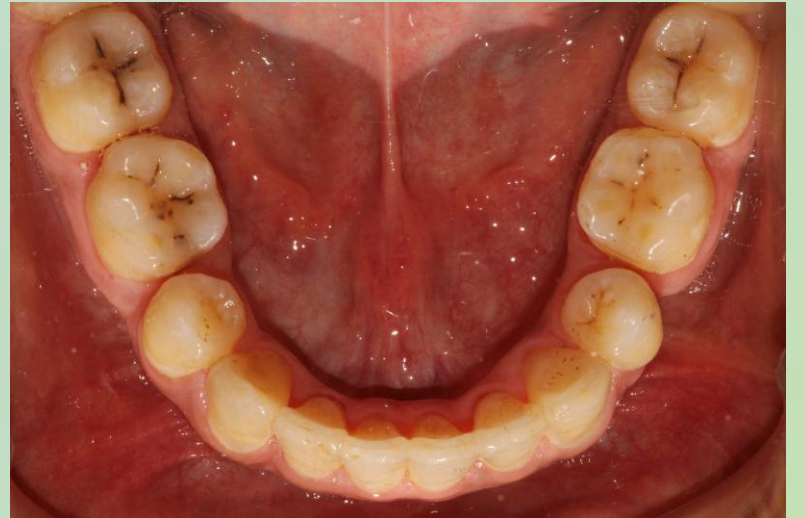





Post Treatment Extraoral Photographs



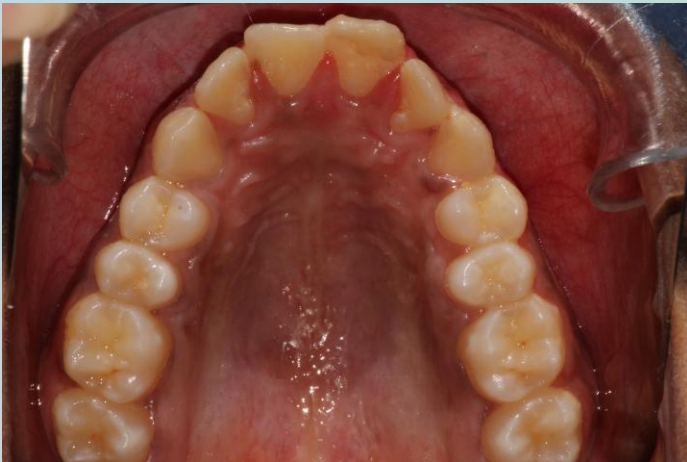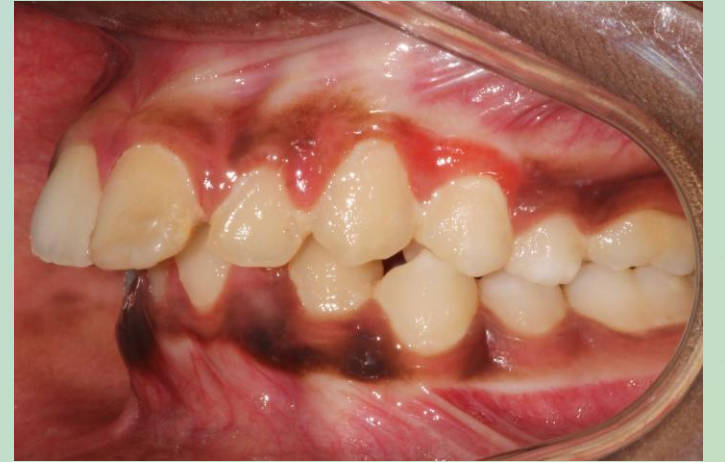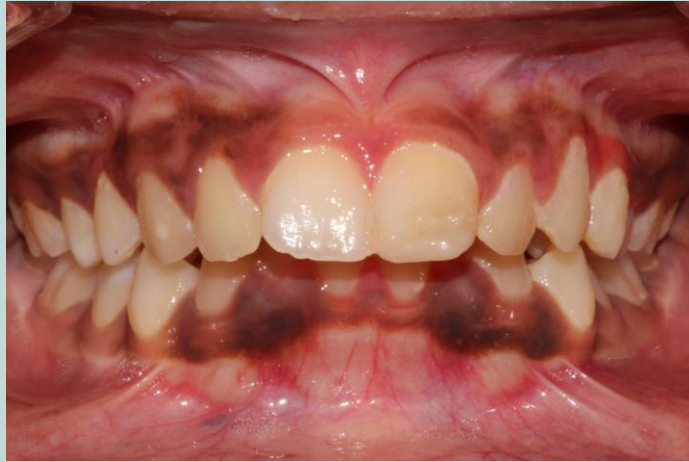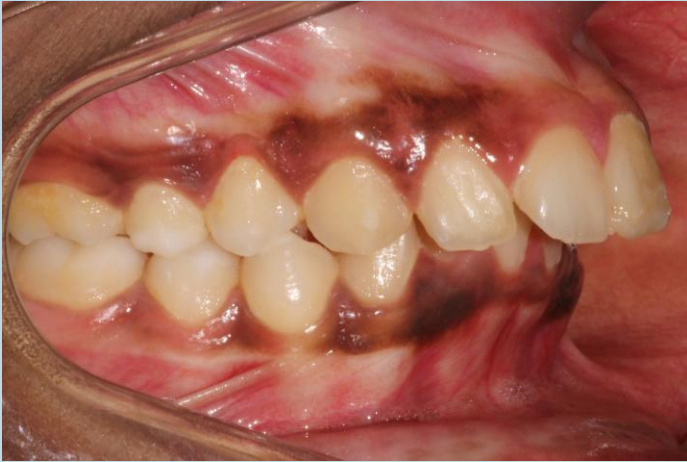Post Treatment Intraoral
Photos



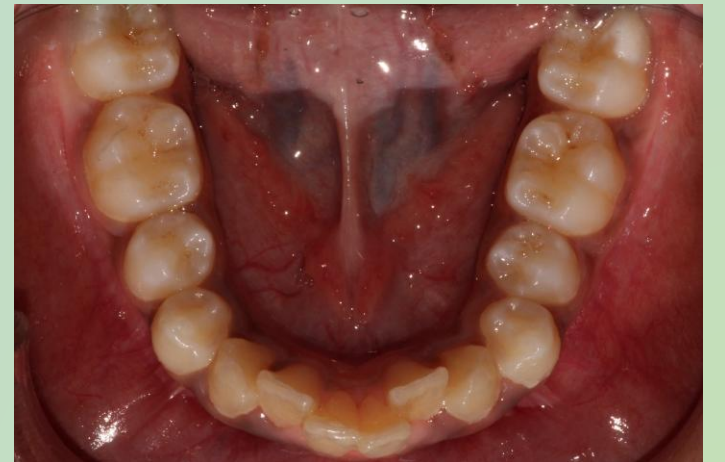*En – masse intrusion in case of vertical maxillary
excess*

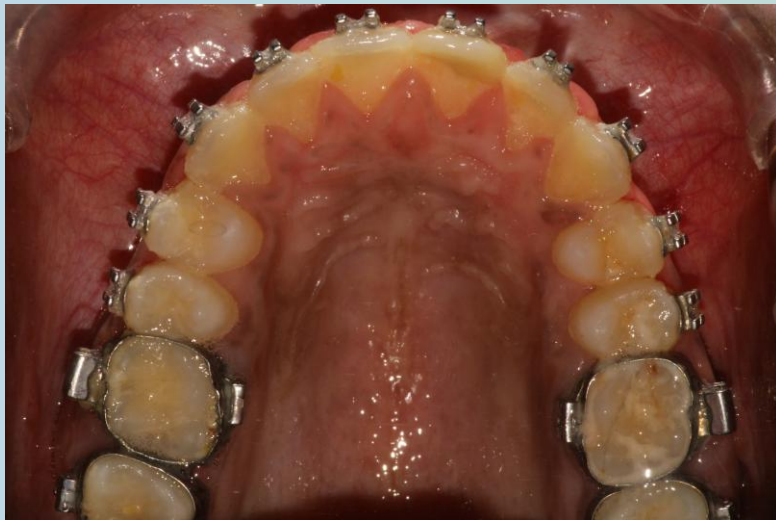
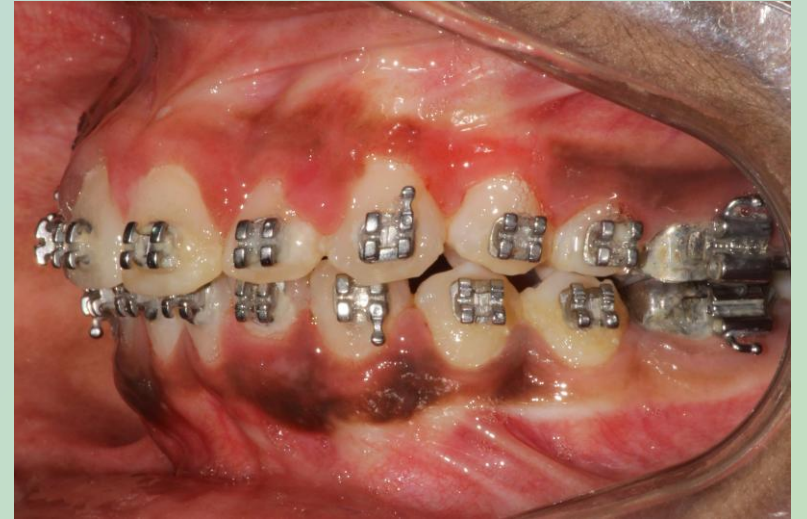
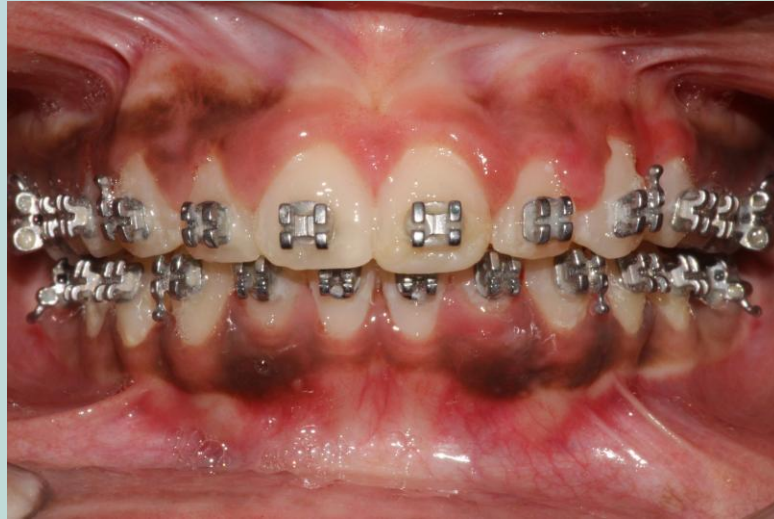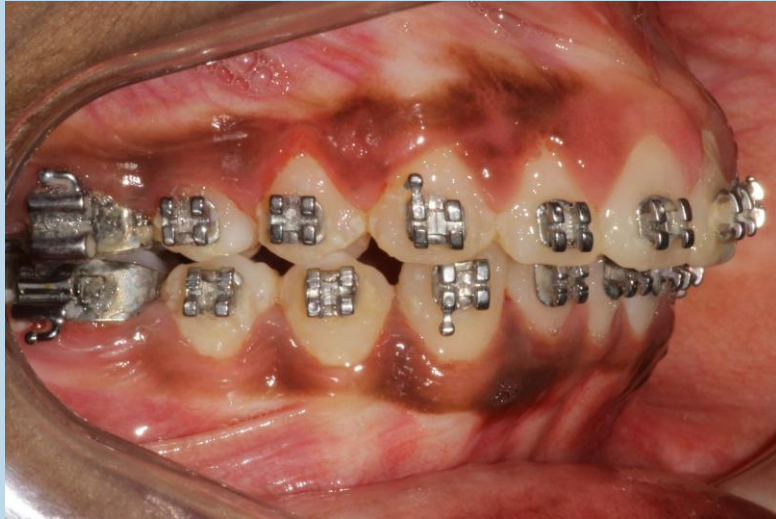Pre - treatment Extraoral Photographs

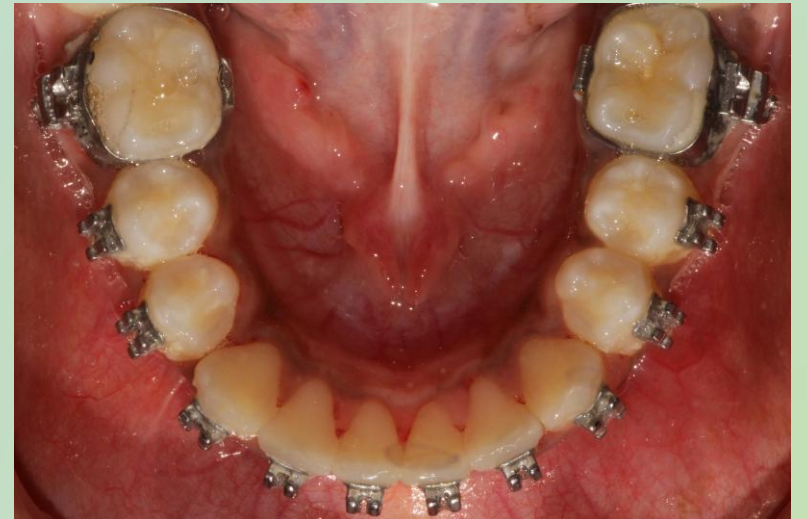

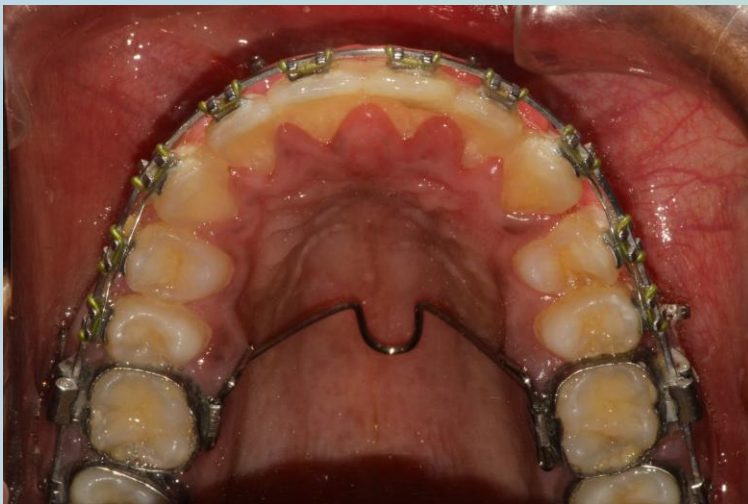
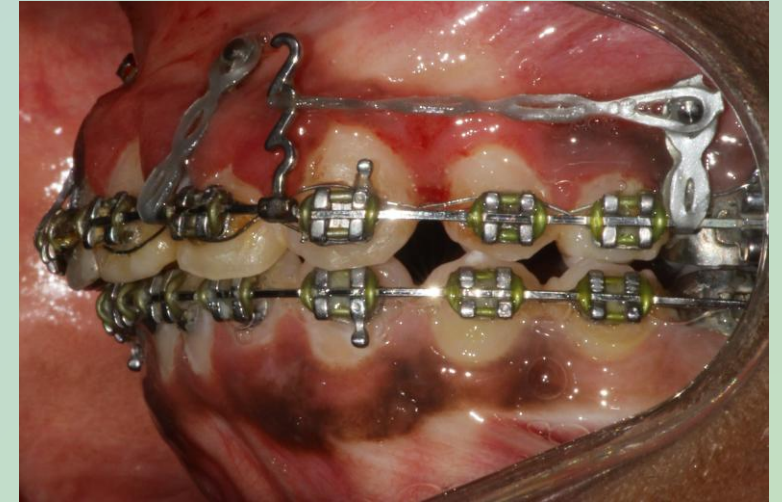
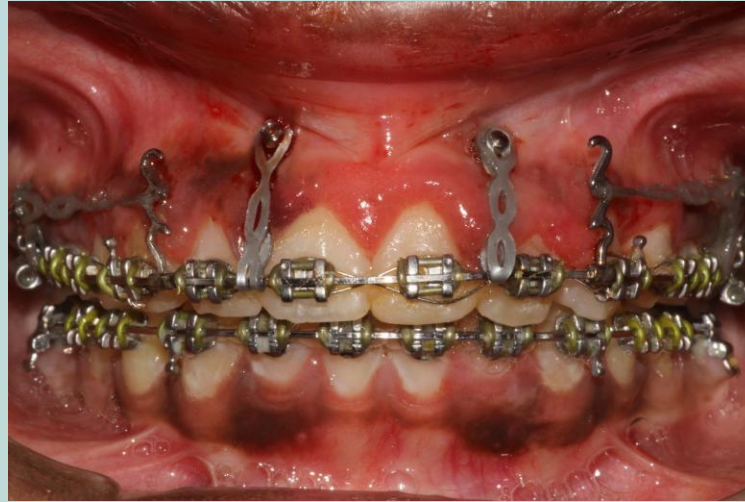
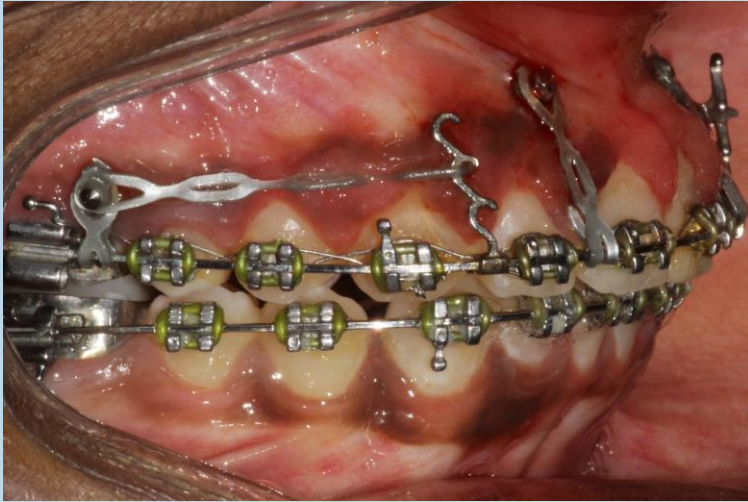
Pre - treatment Intraoral
Photographs



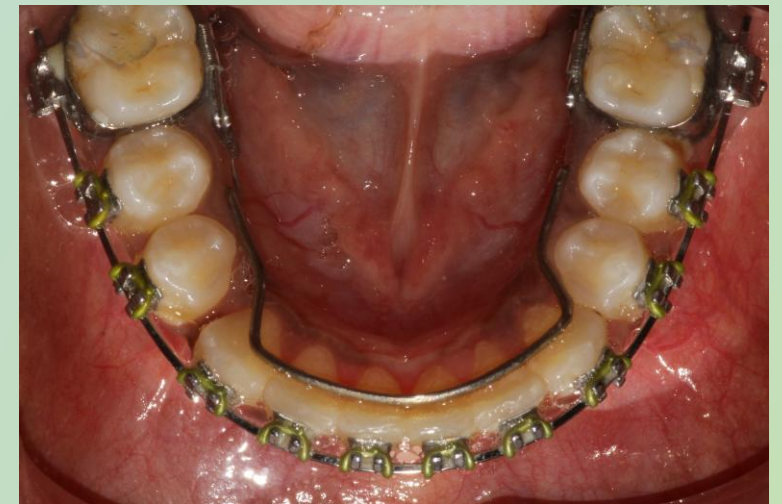


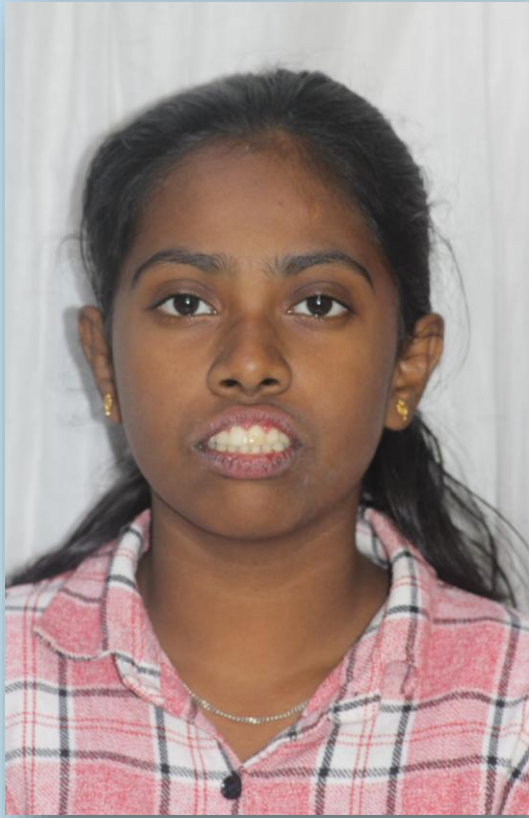
Leveling and Aligning
Intraoral Photographs



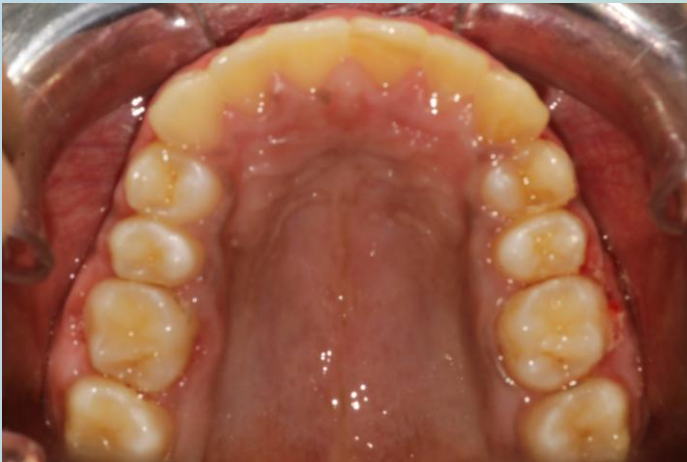
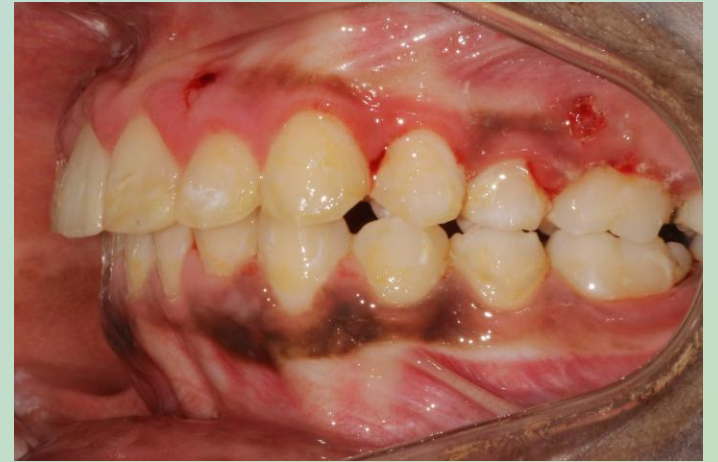
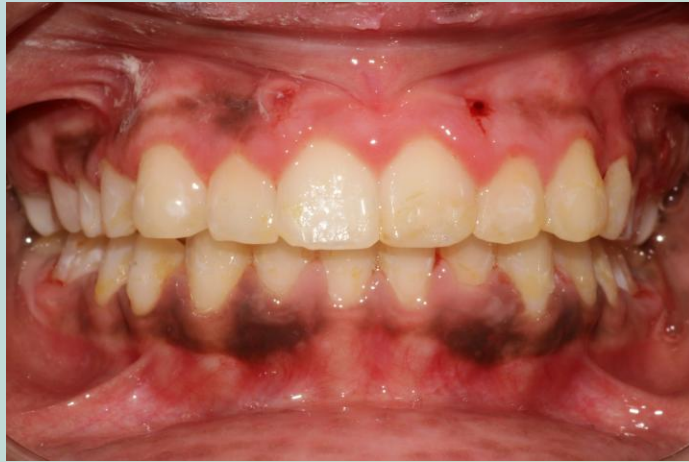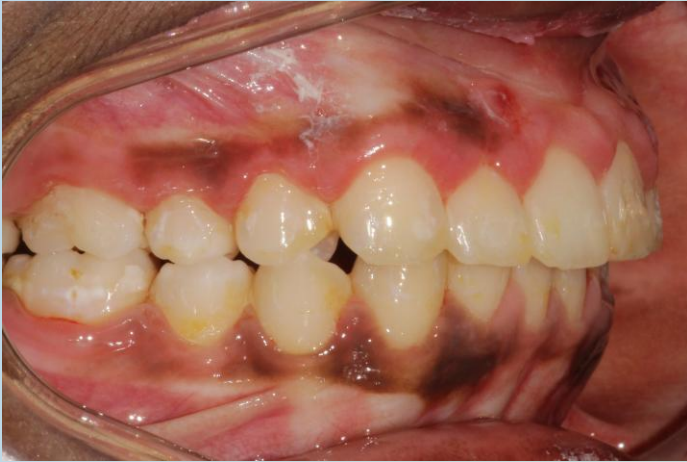Posterior and Anterior placement of Tads for en - masse Distalization and Vertical Maxillary Impaction

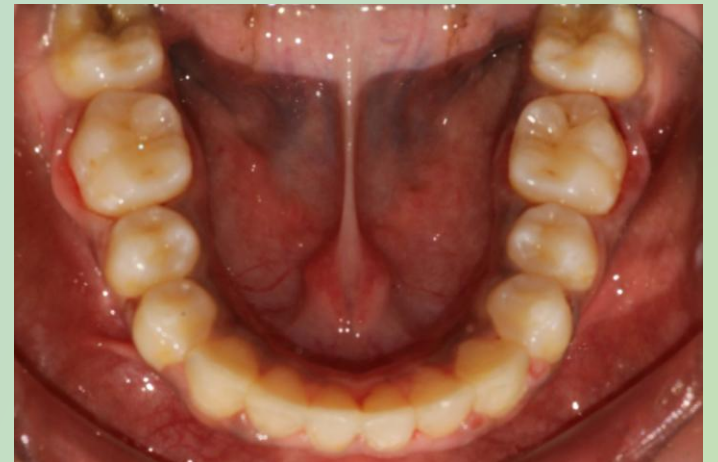






Post - treatment Extraoral Photographs



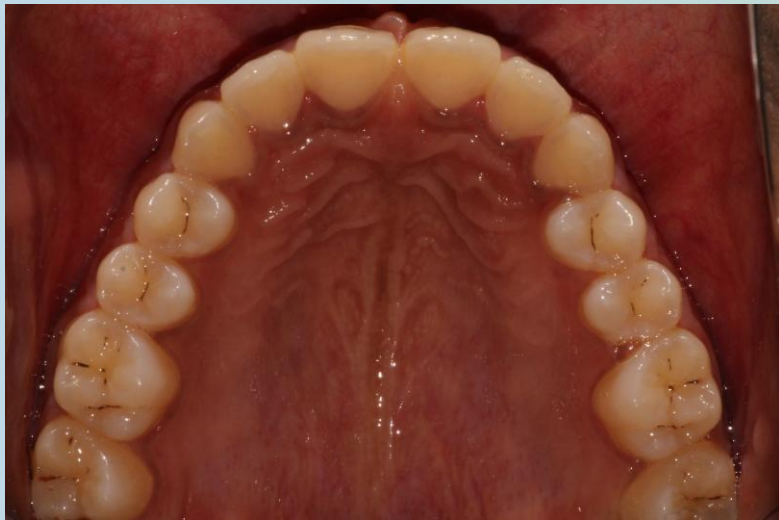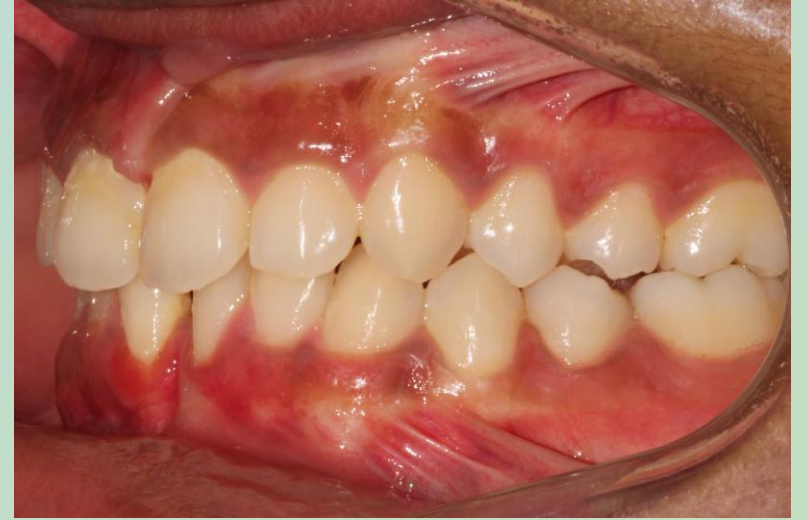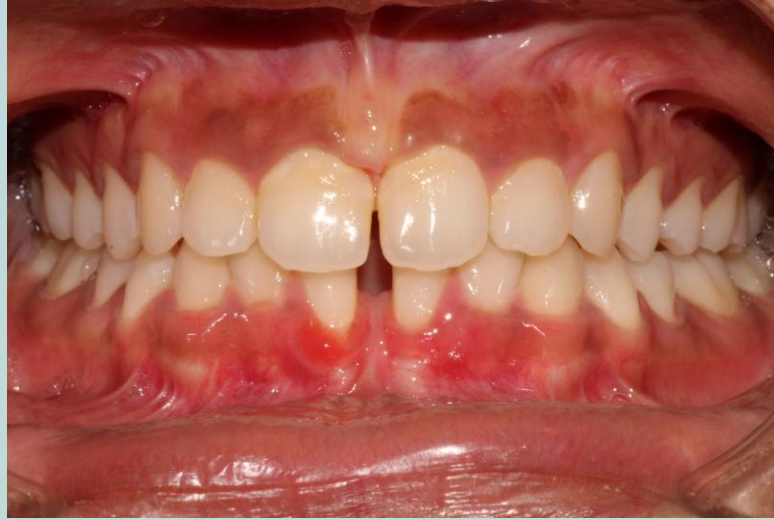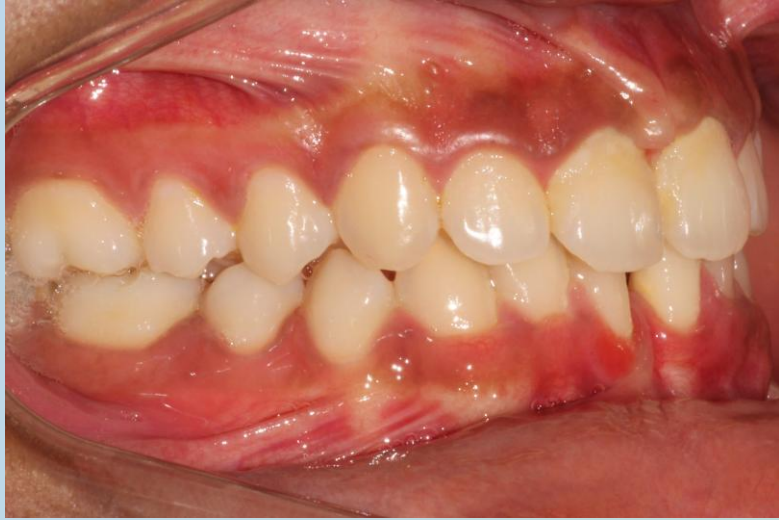Post - treatment Intraoral
Photographs



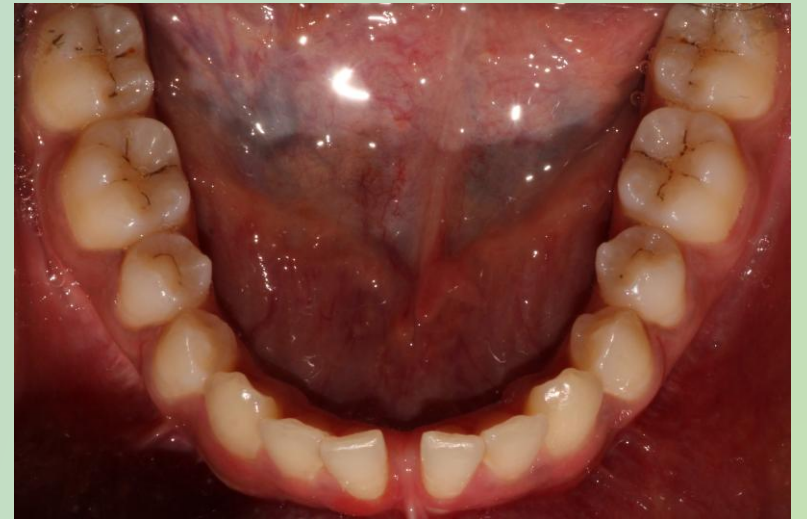Midline Diastema with High Frenal Attachment

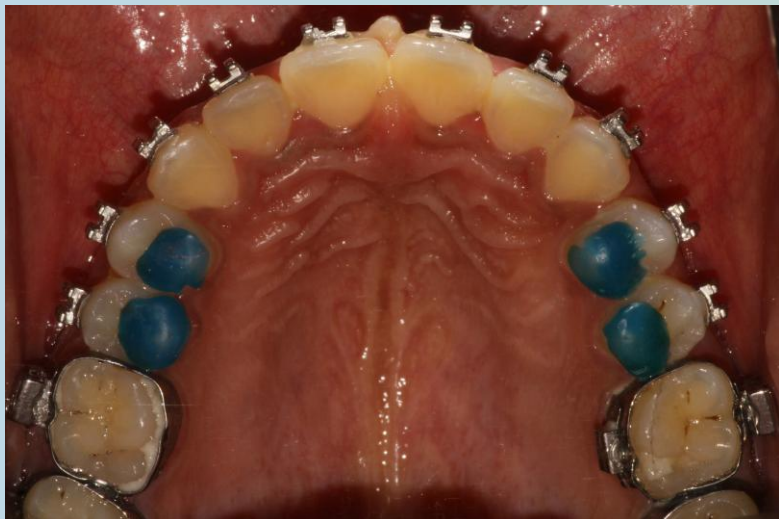
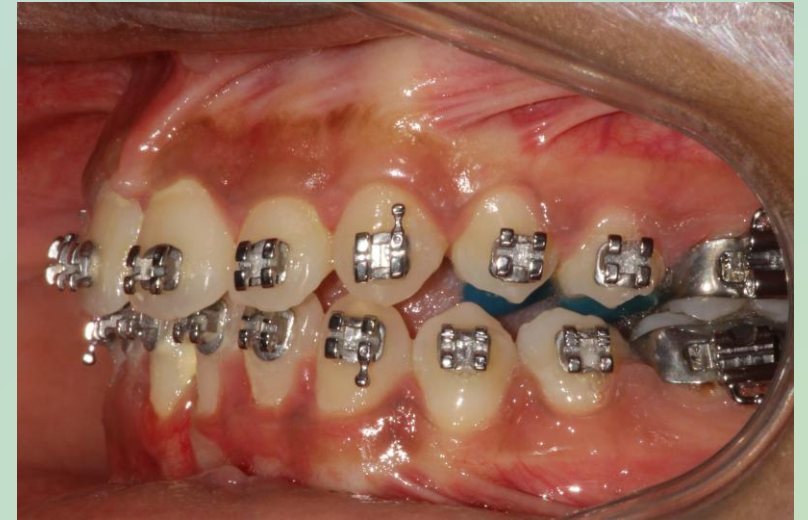
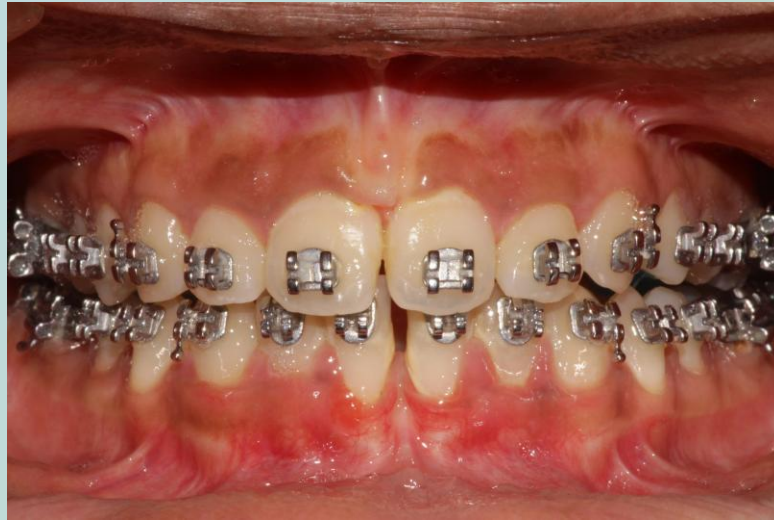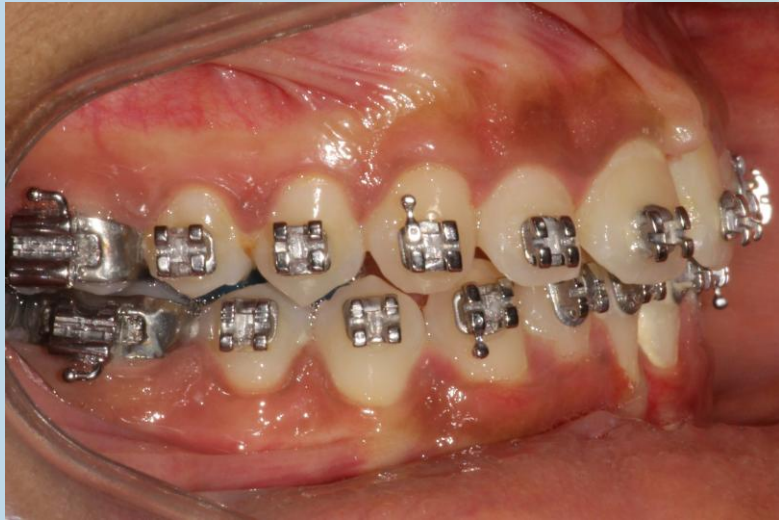Pre - treatment Extraoral Photographs

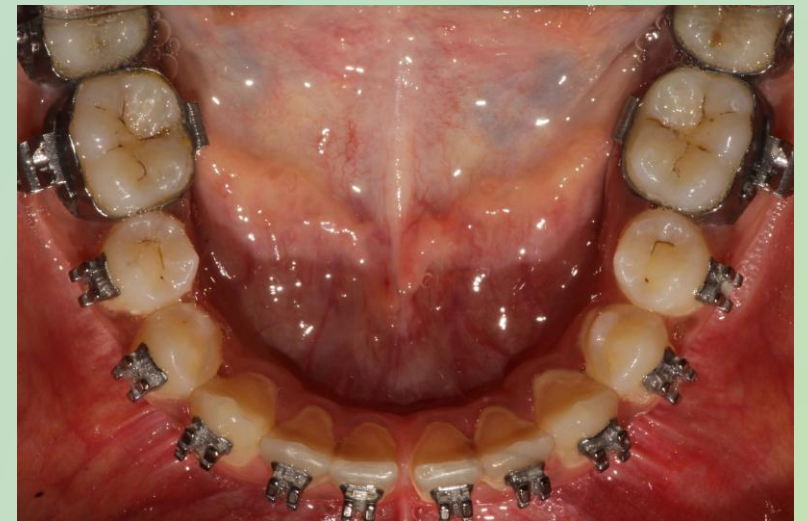

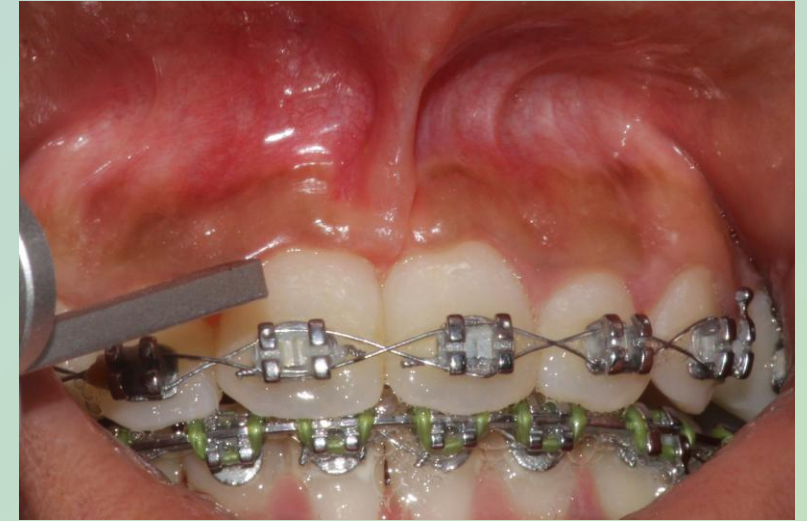
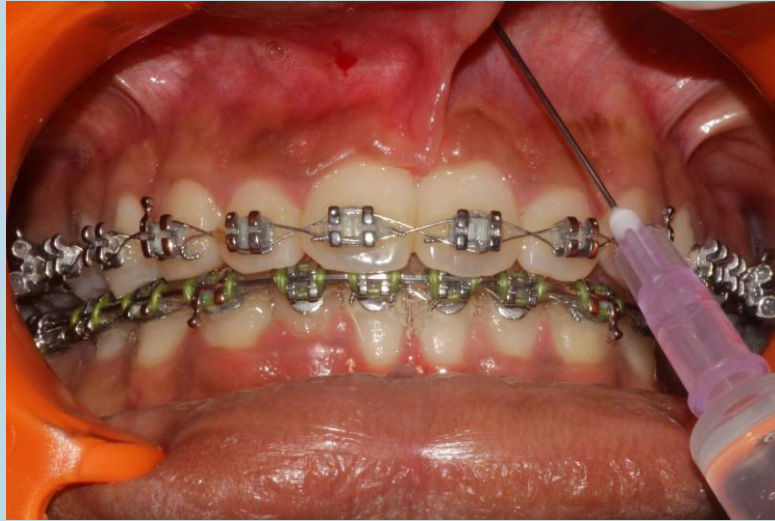Pre - treatment Intraoral
Photographs



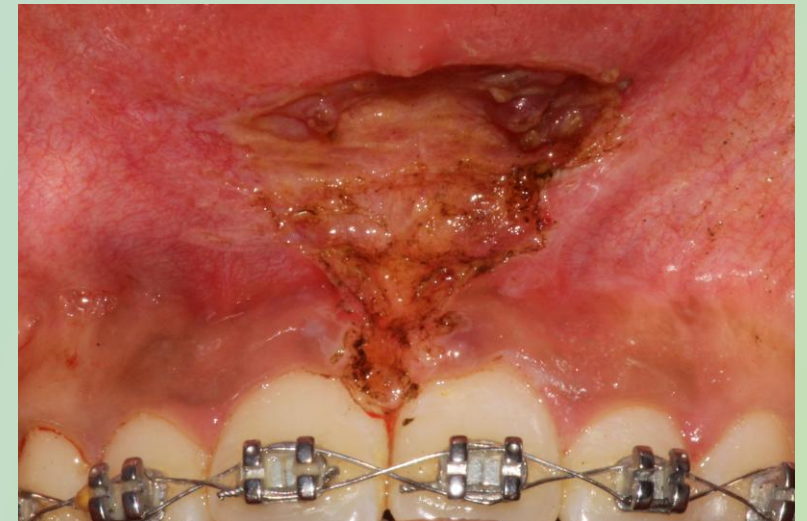
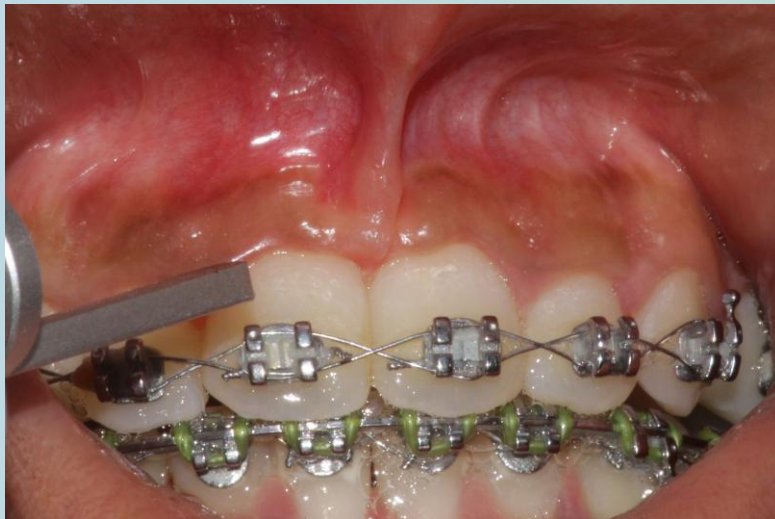


Leveling and Aligning
Intraoral Photographs



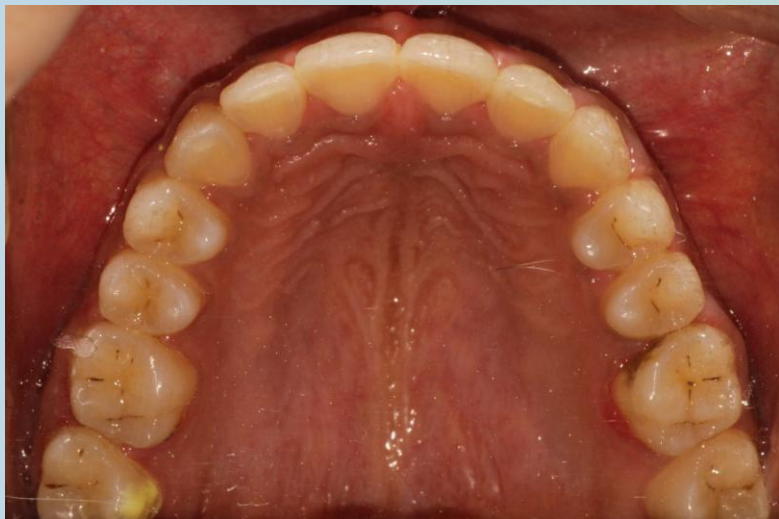
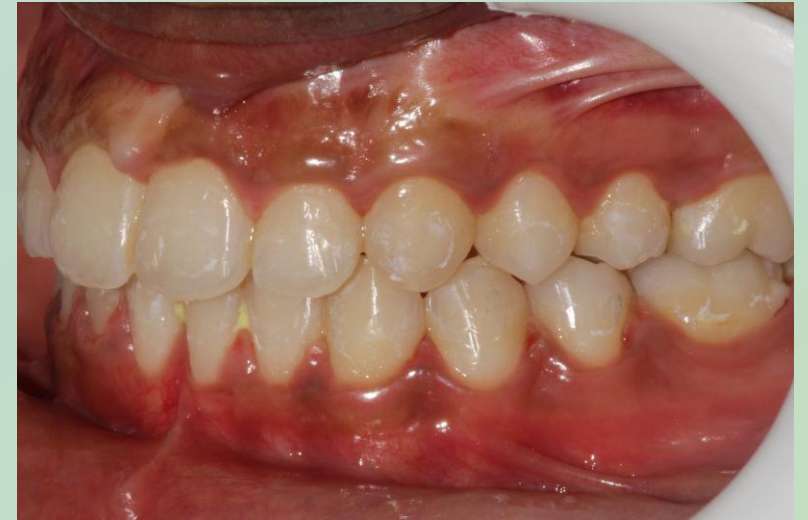
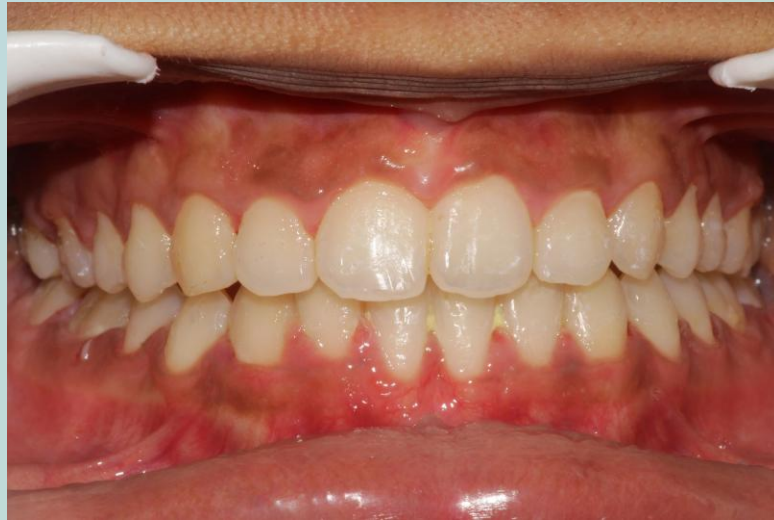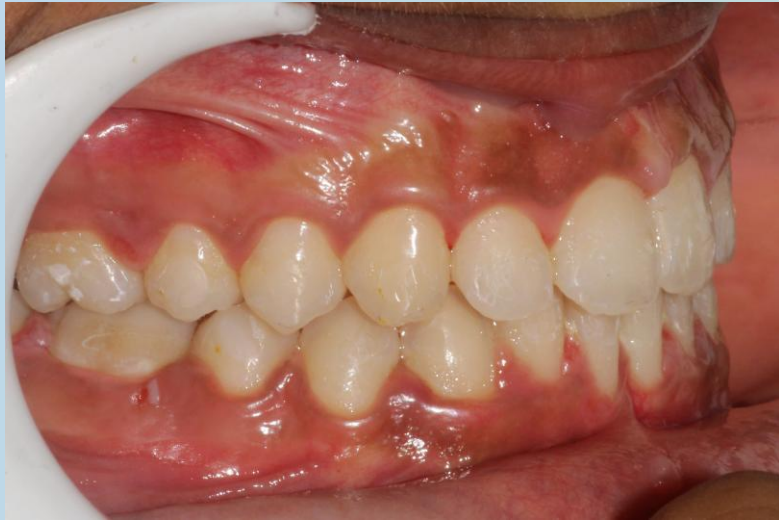Frenectomy

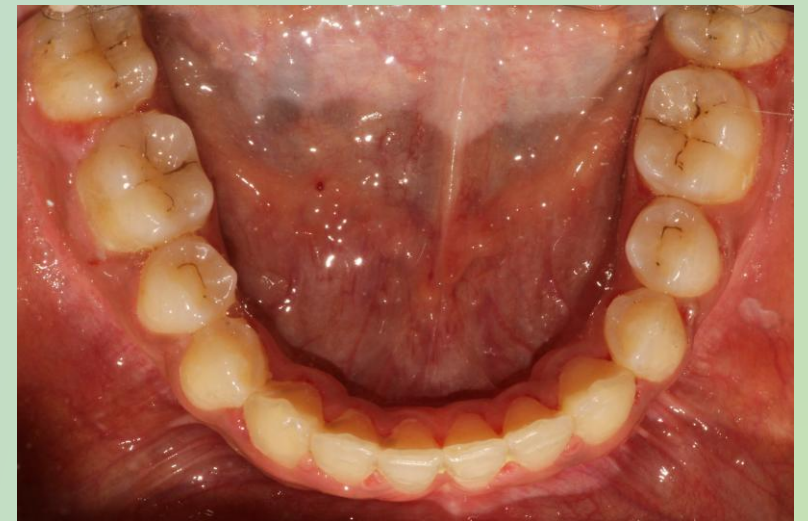





Post - treatment Extraoral Photographs



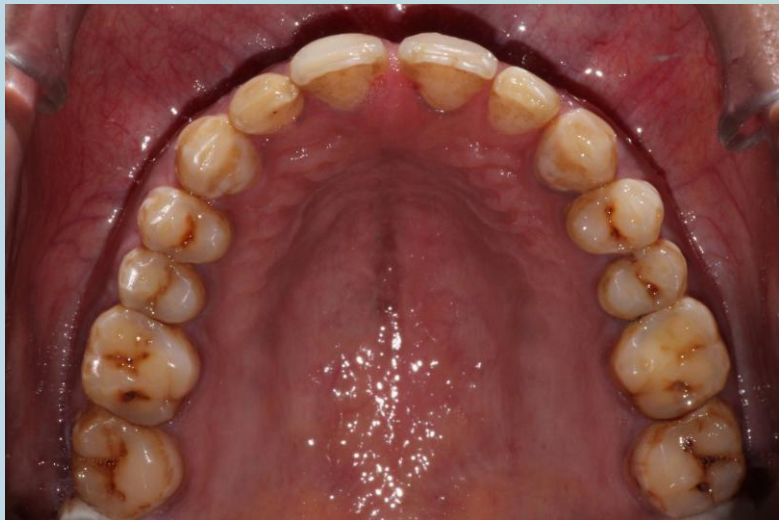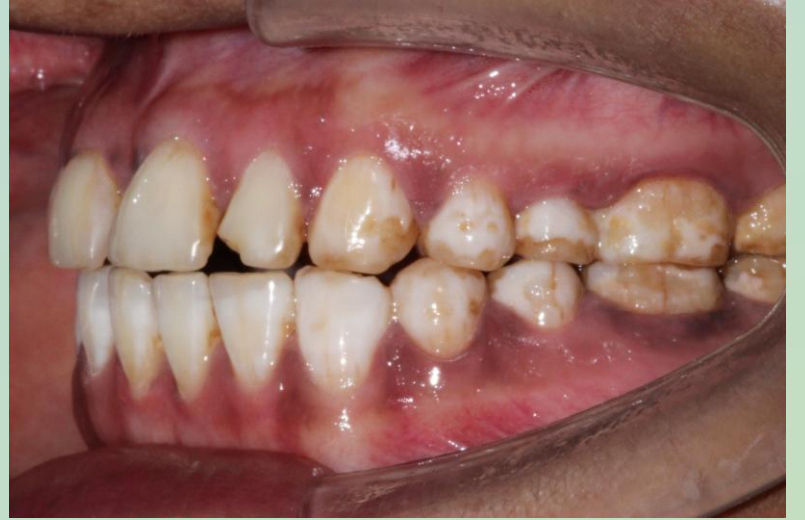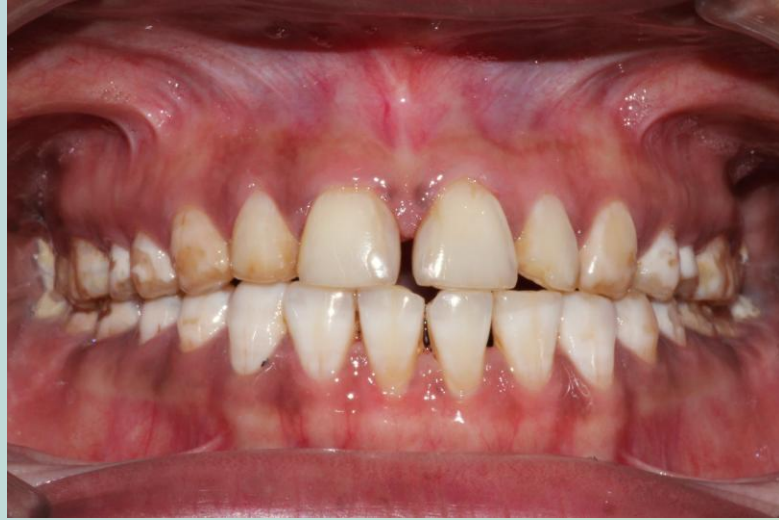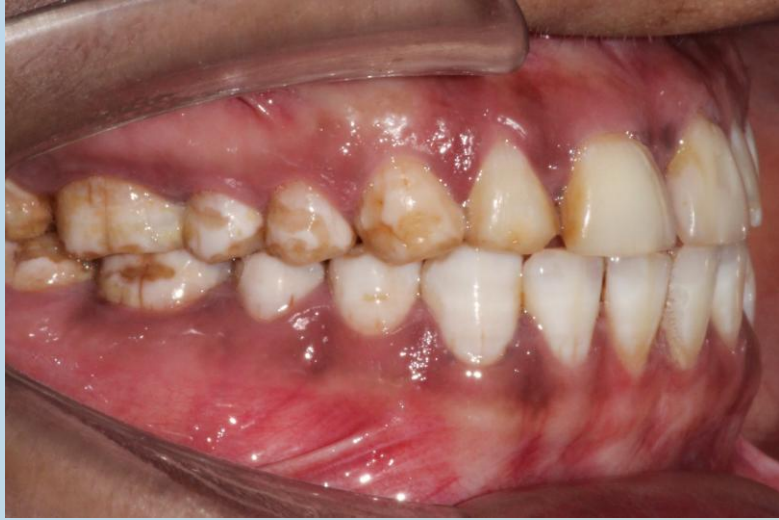Post - treatment Intraoral
Photographs



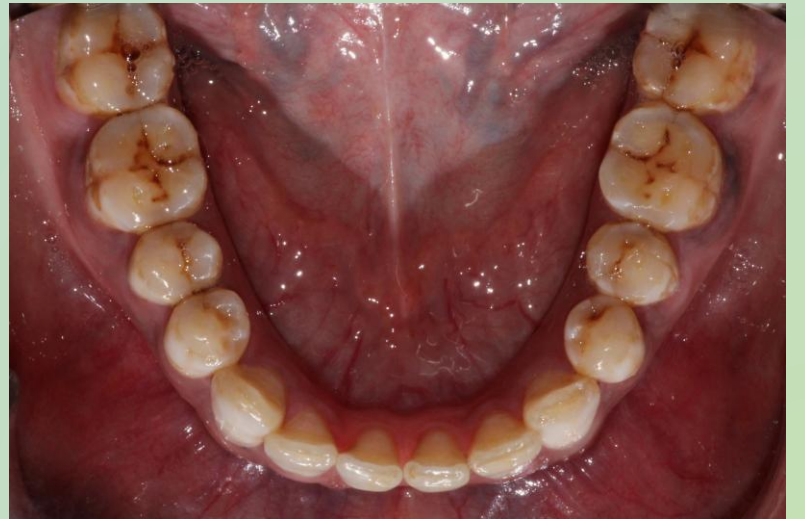Midline Diastema with High Frenal Attachment

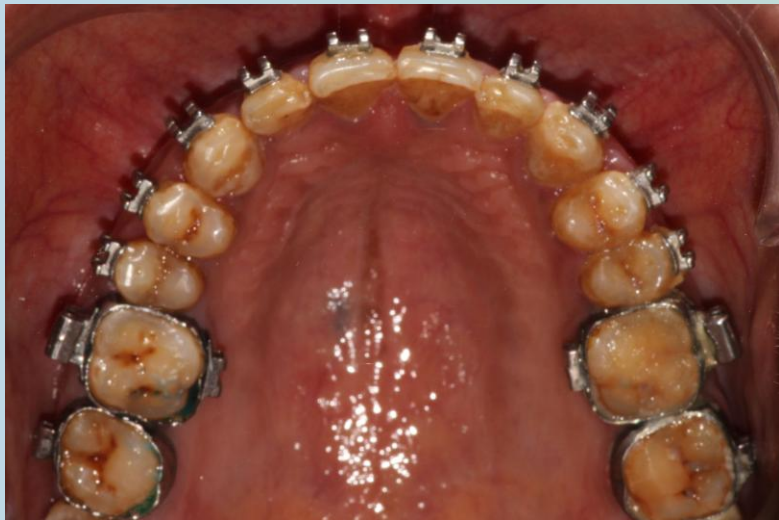
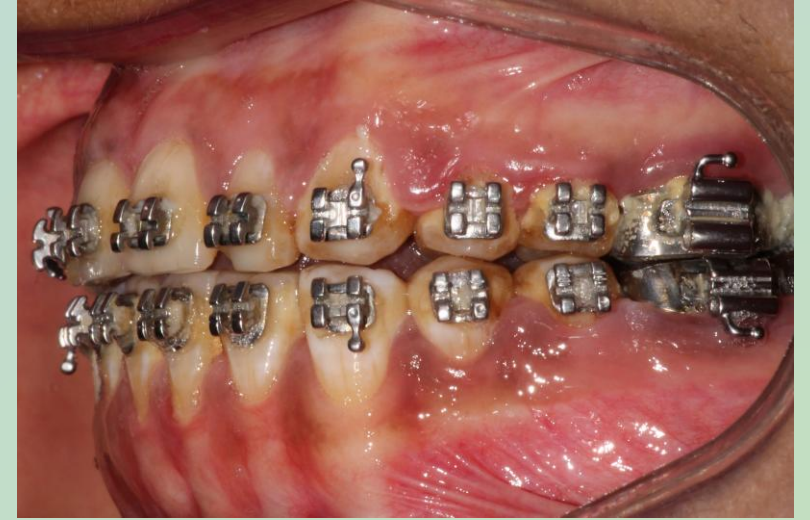
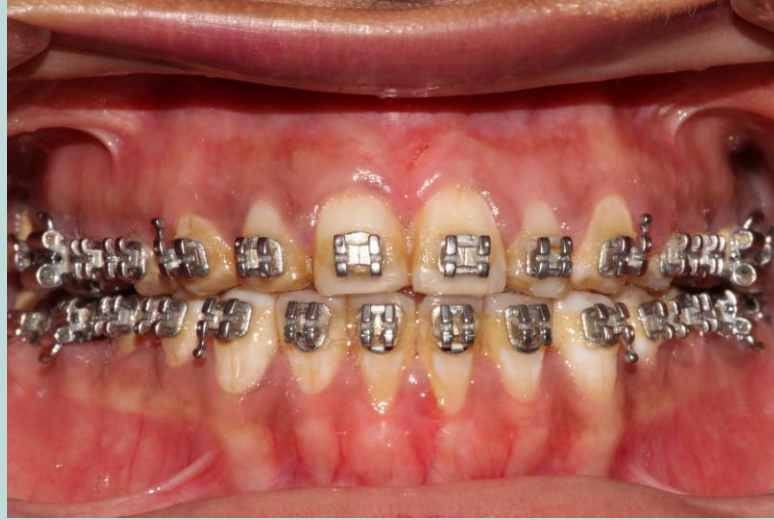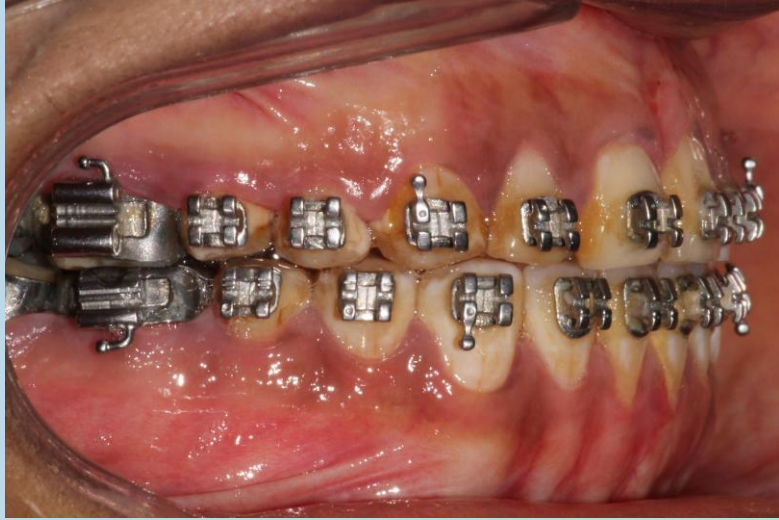Pre - treatment Extraoral Photographs

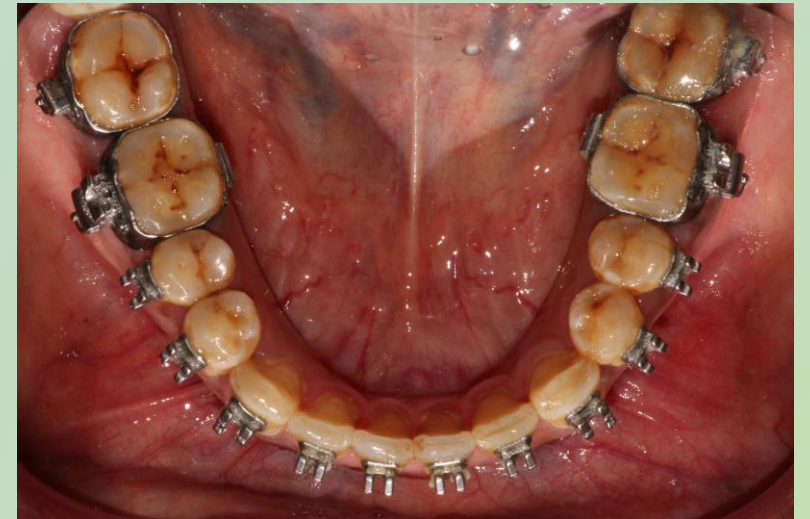

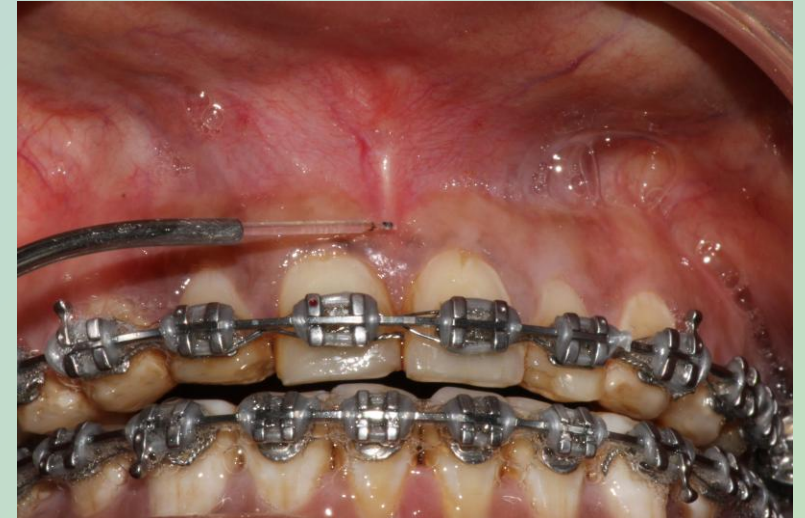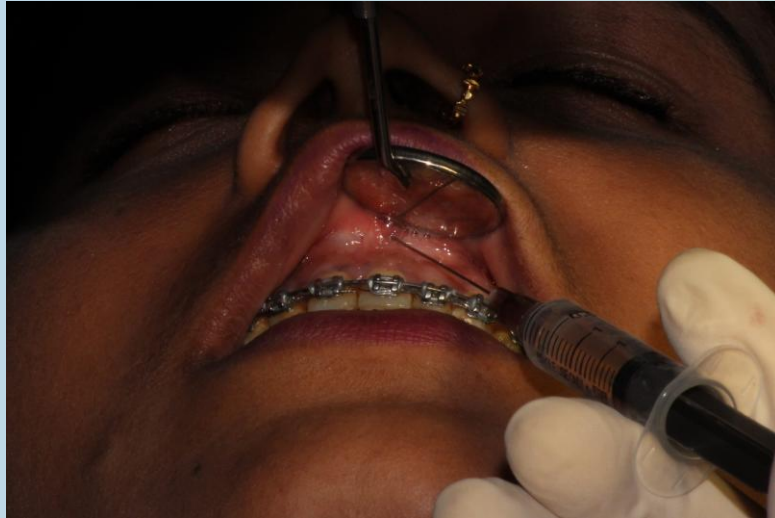Pre - treatment Intraoral
Photographs



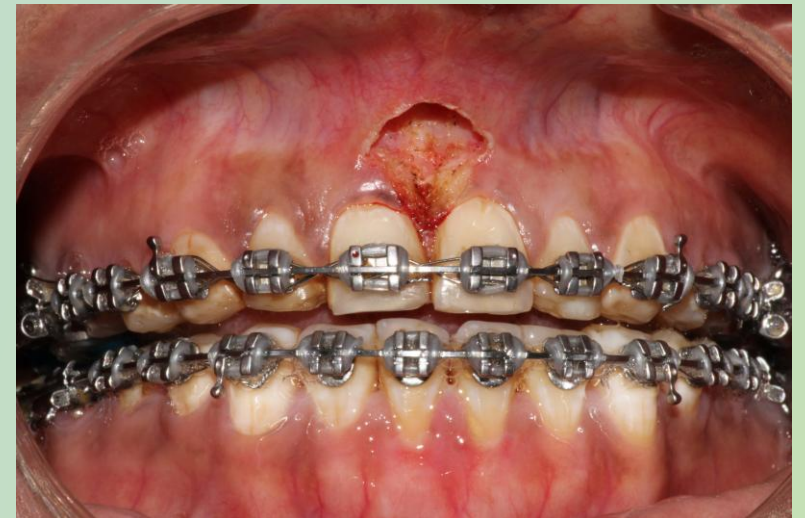
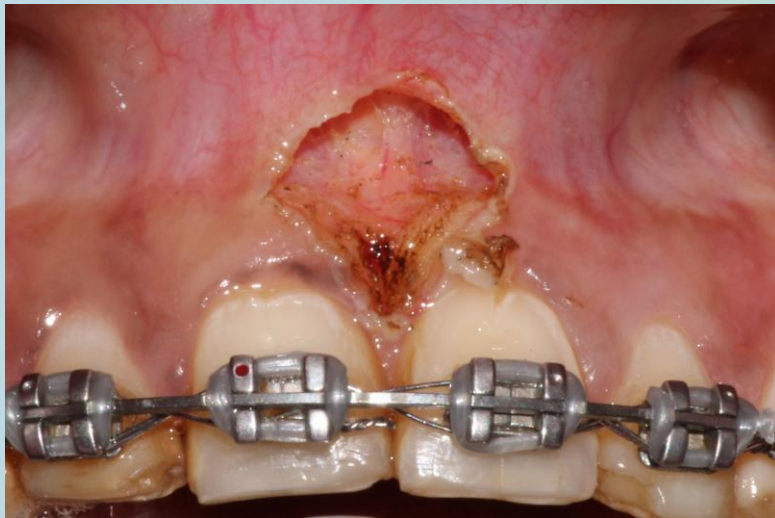


Leveling and Aligning
Intraoral Photographs

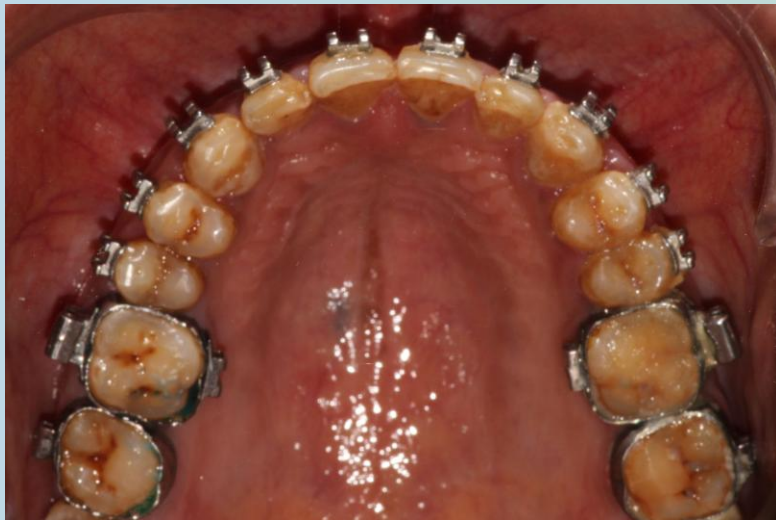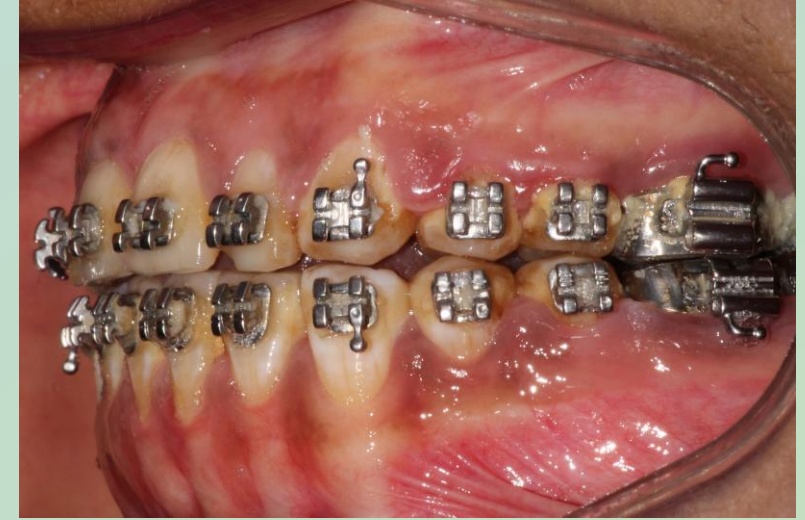

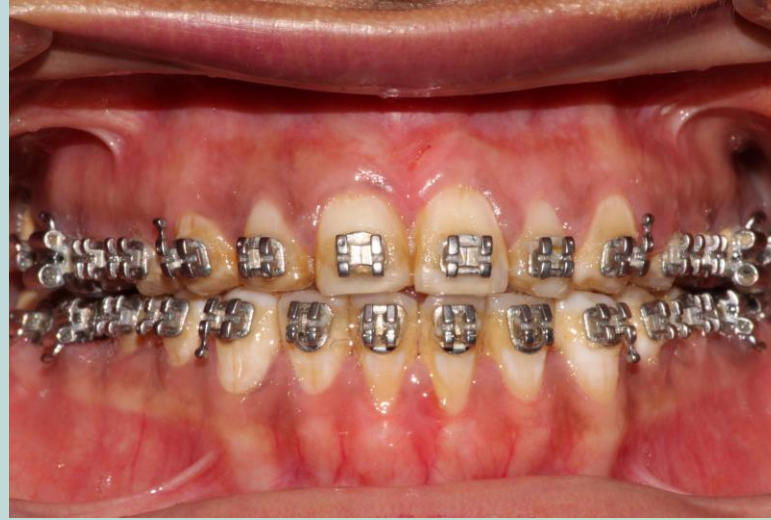
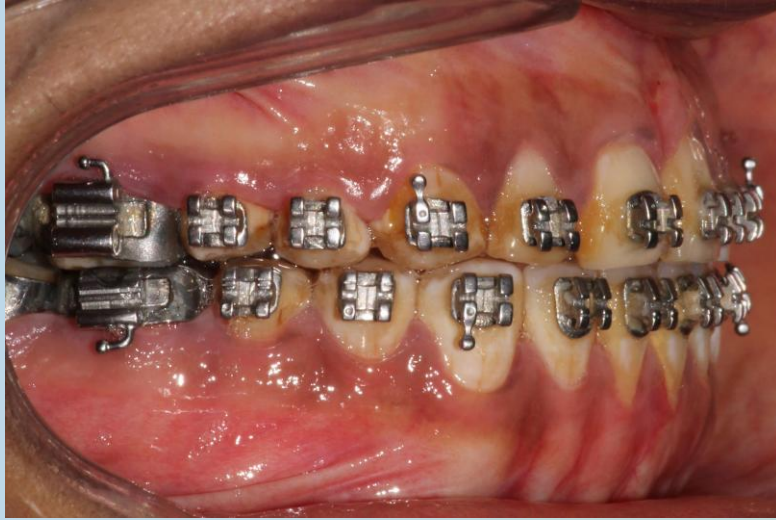

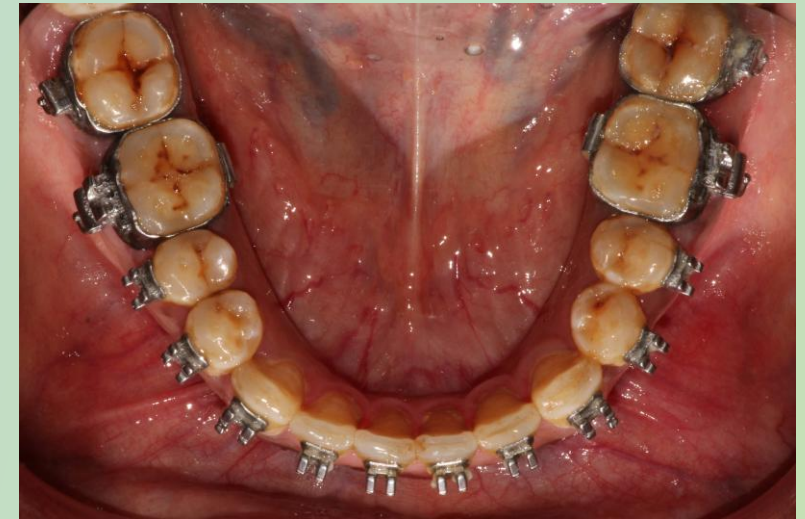
Frenectomy

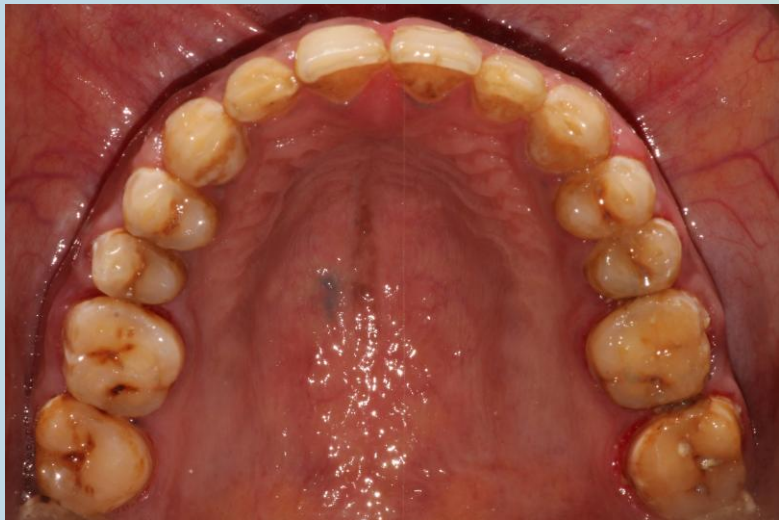
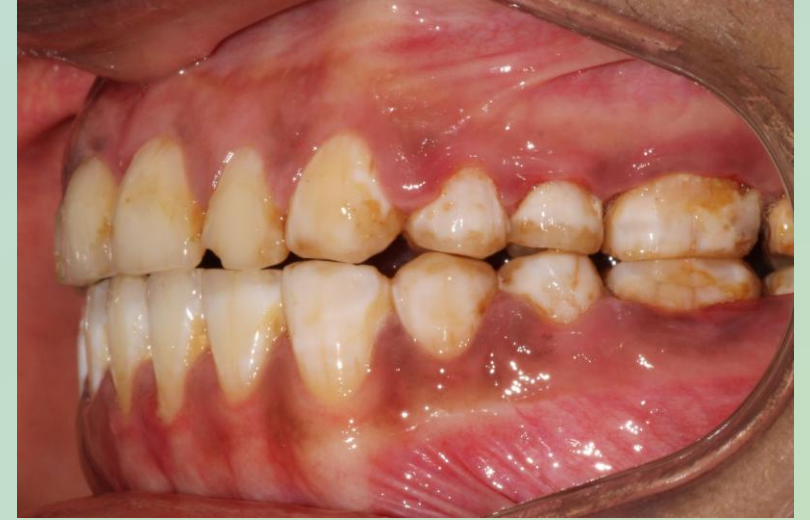
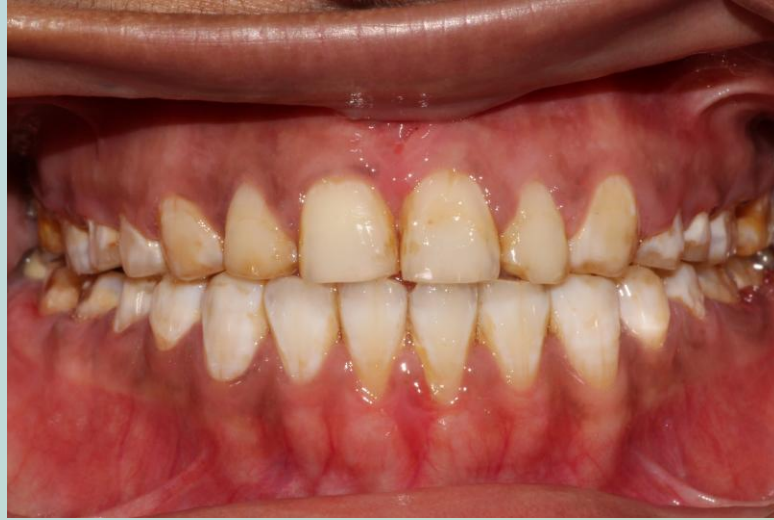
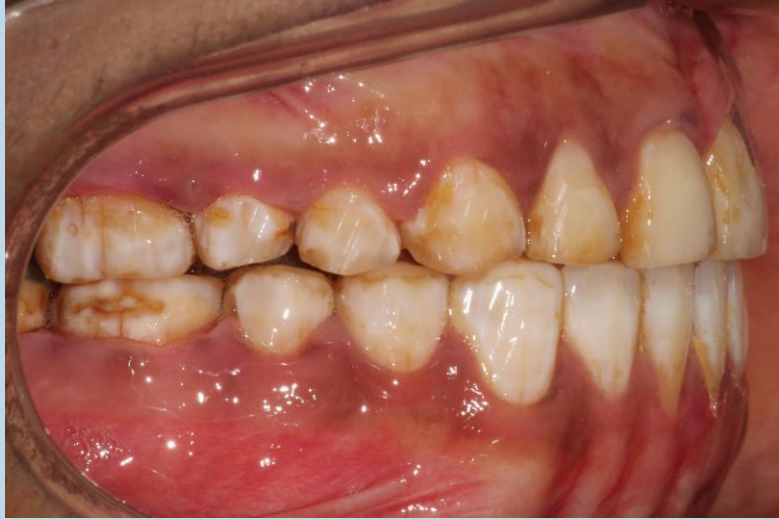*Interdisciplinary Orthodontics –
Periodontics: Frenectomy – 4a*

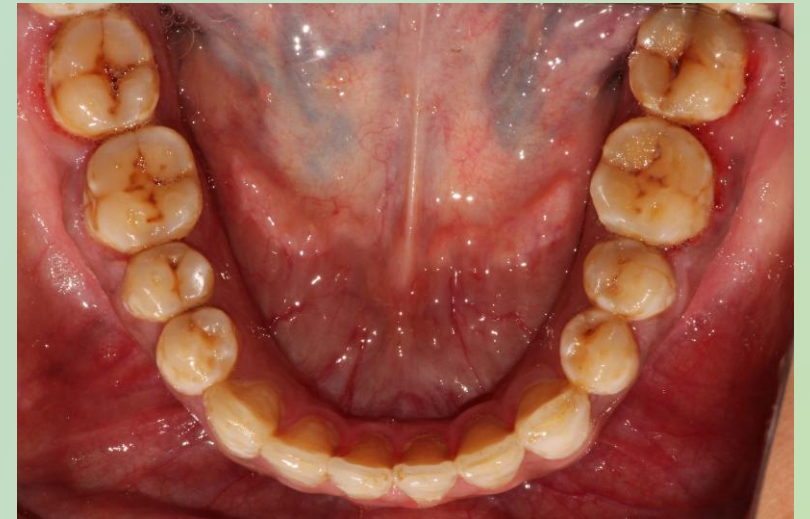


Post Frenectomy and Midline
Diastema closure Intraoral
Photographs

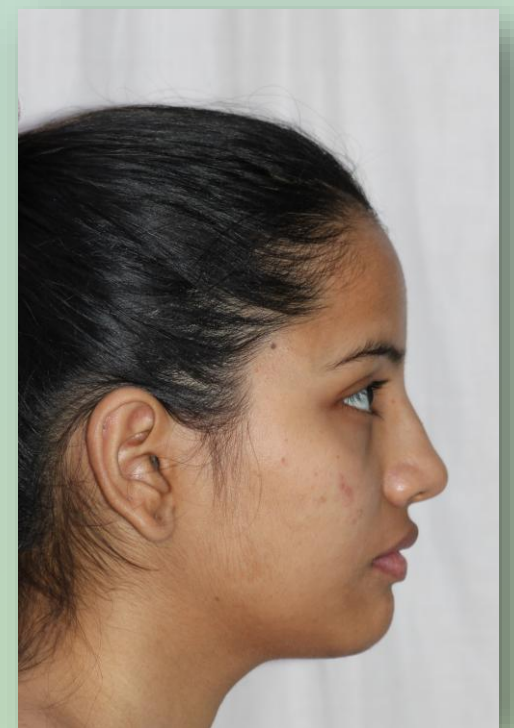




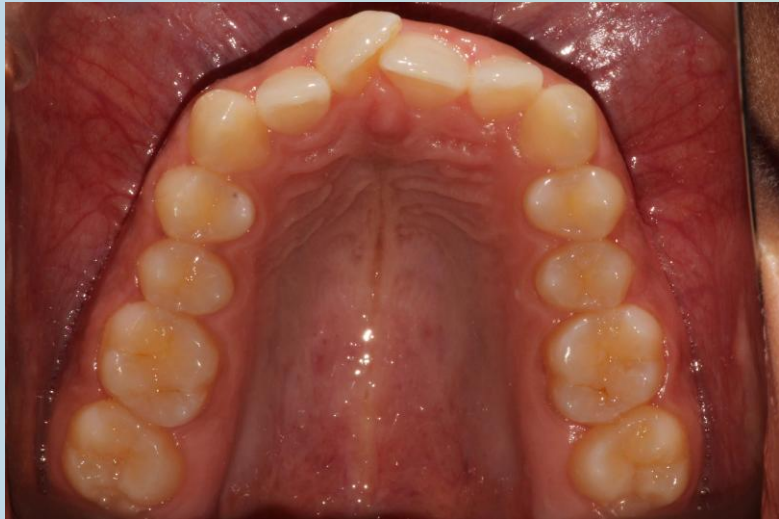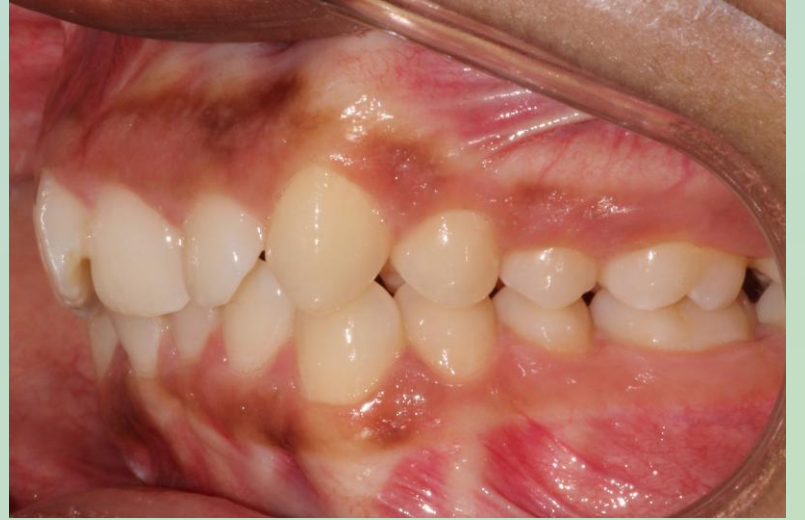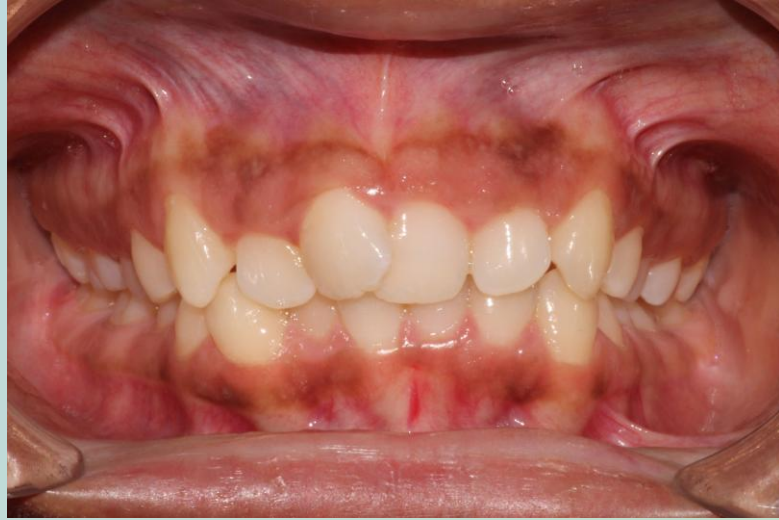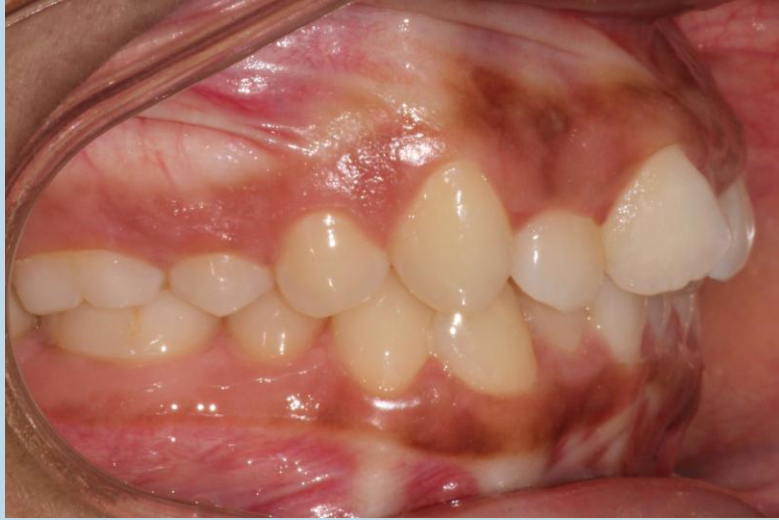Post - treatment Intraoral
Photographs



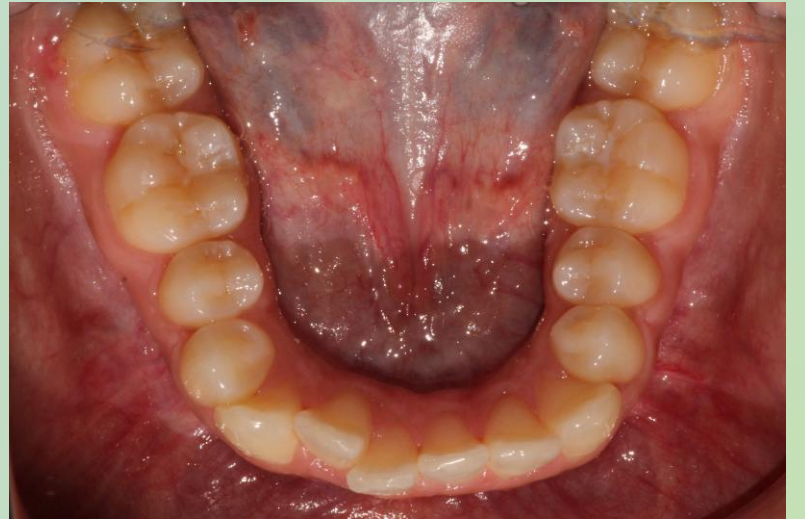
Ceramic Brackets

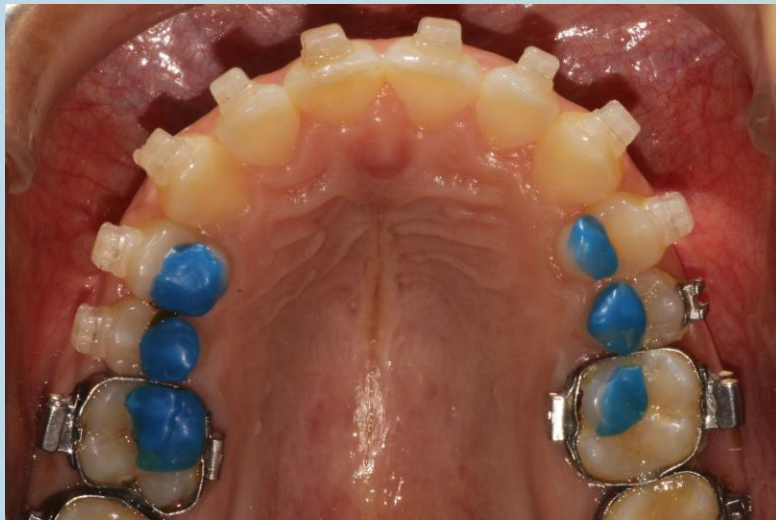
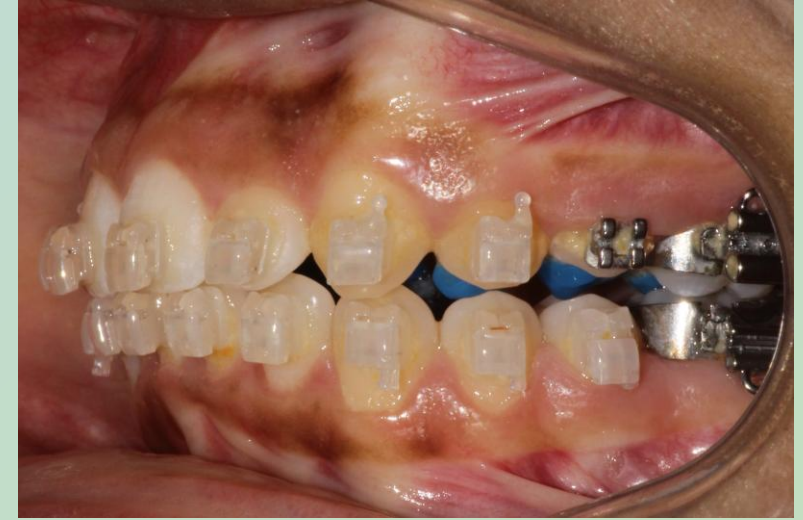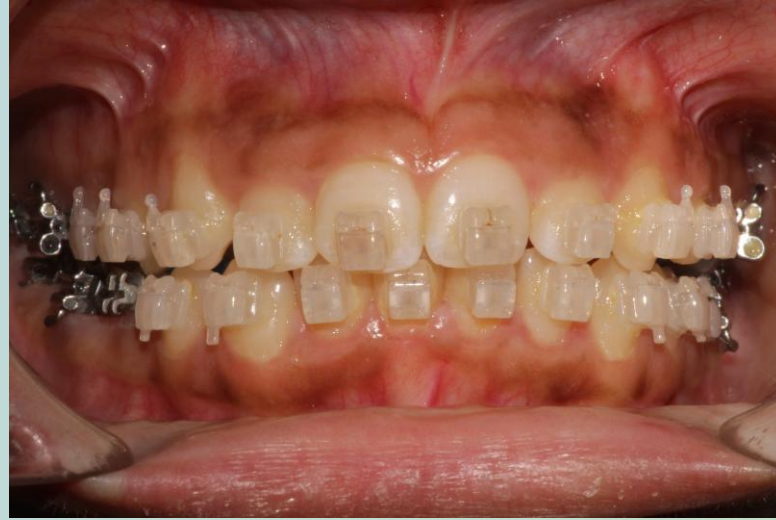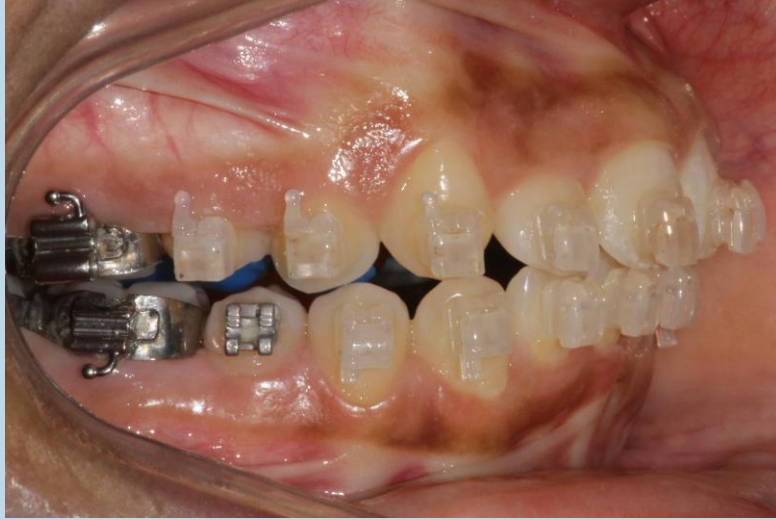


Pre - treatment Extraoral Photographs

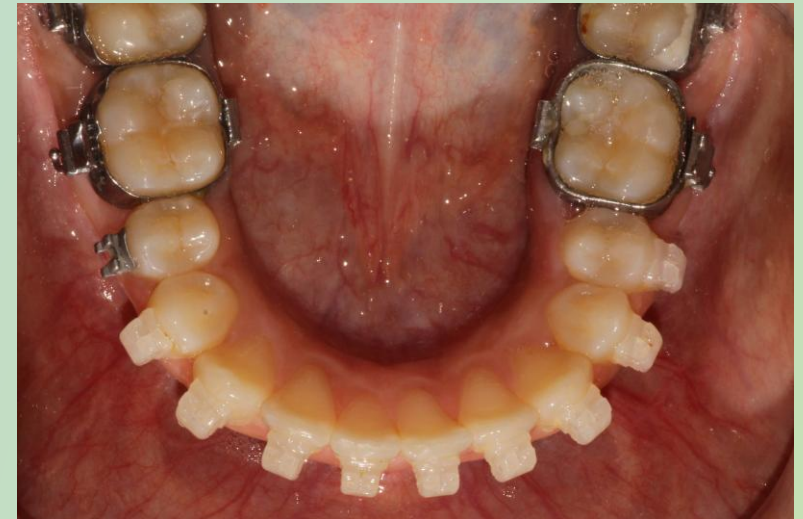


Pre - treatment Intraoral
Photographs



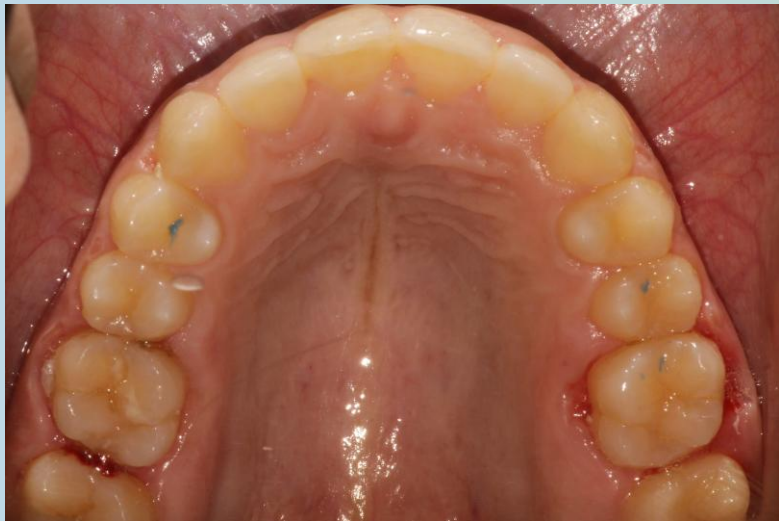
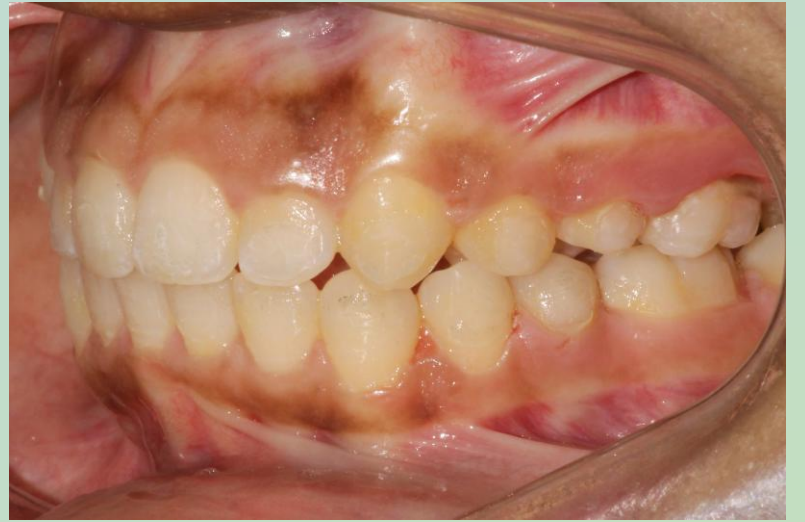
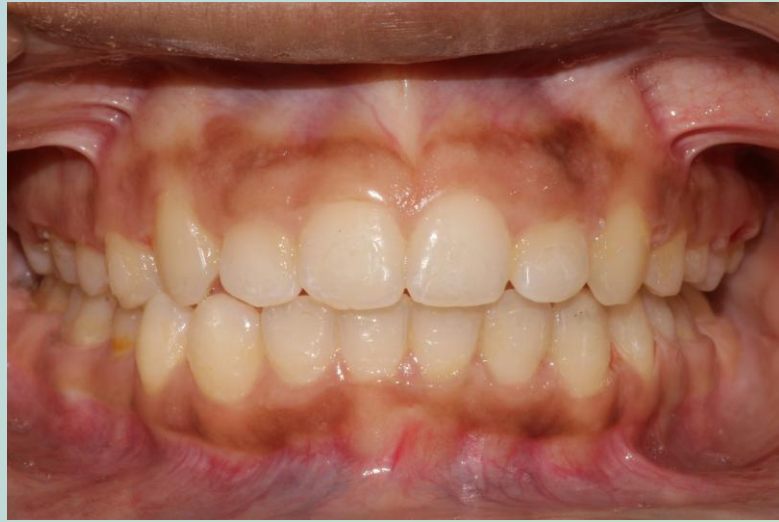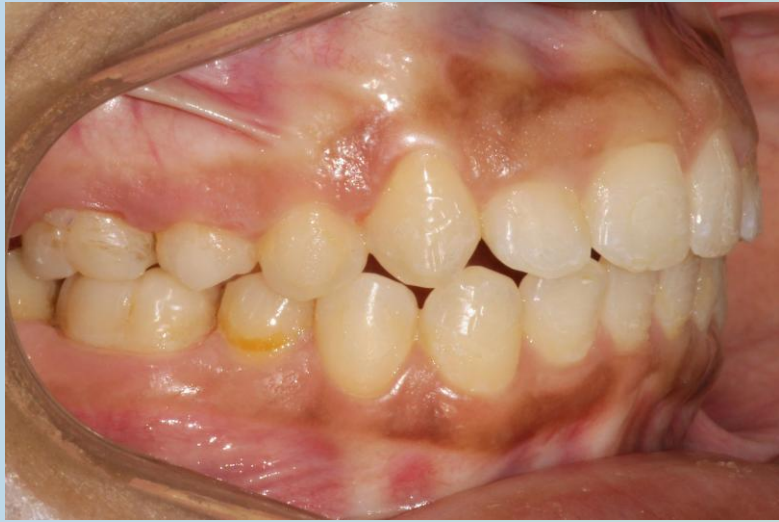Leveling and Aligning
Intraoral Photographs

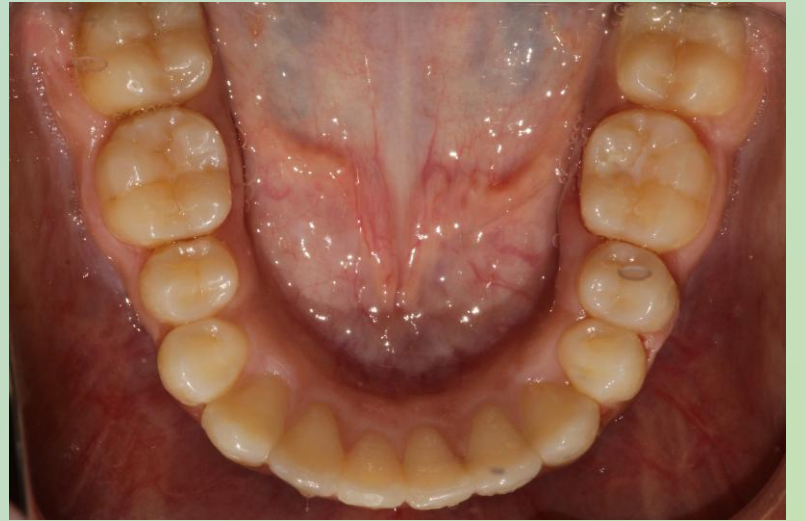




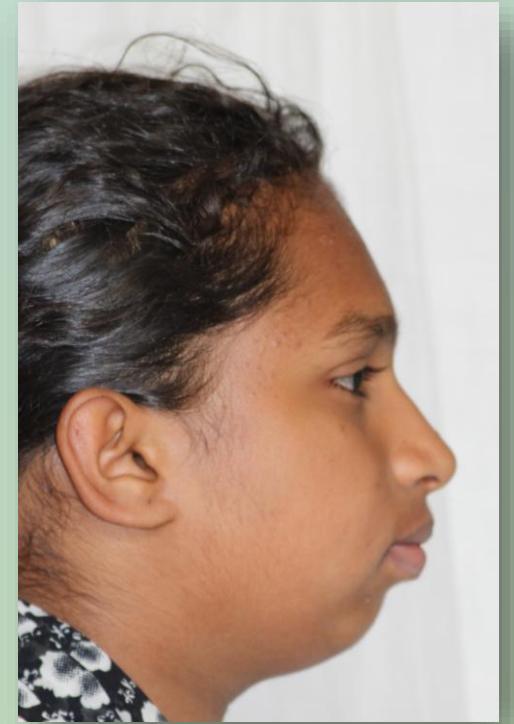Post - treatment Extraoral Photographs



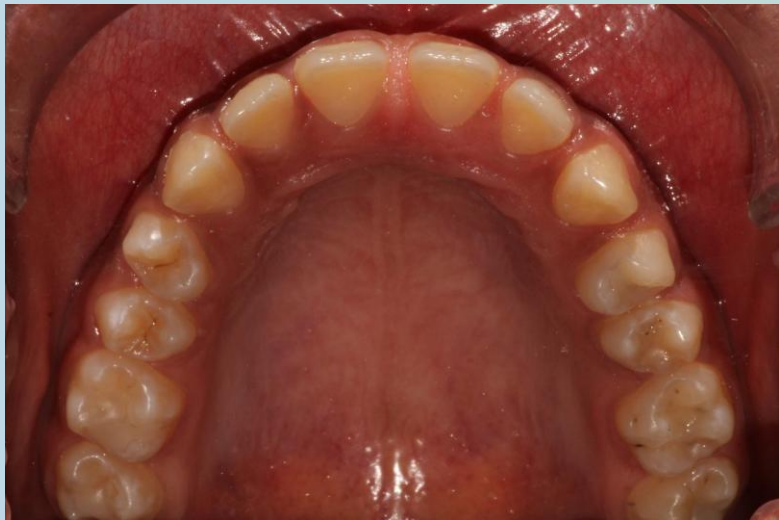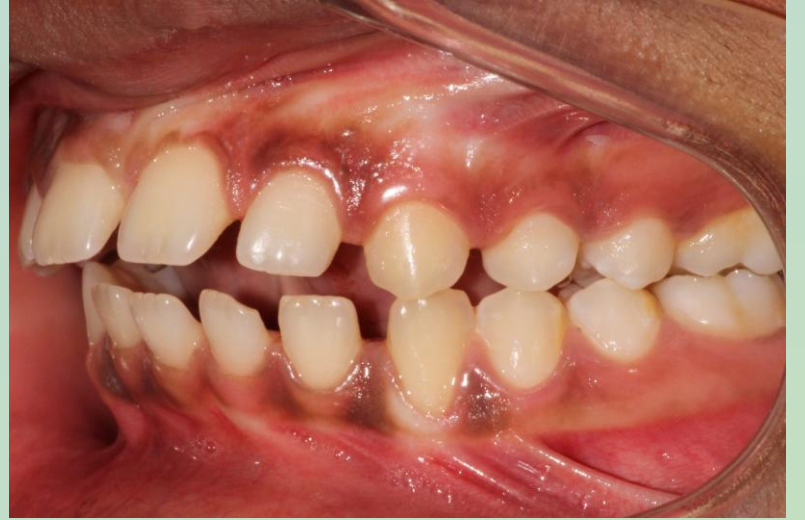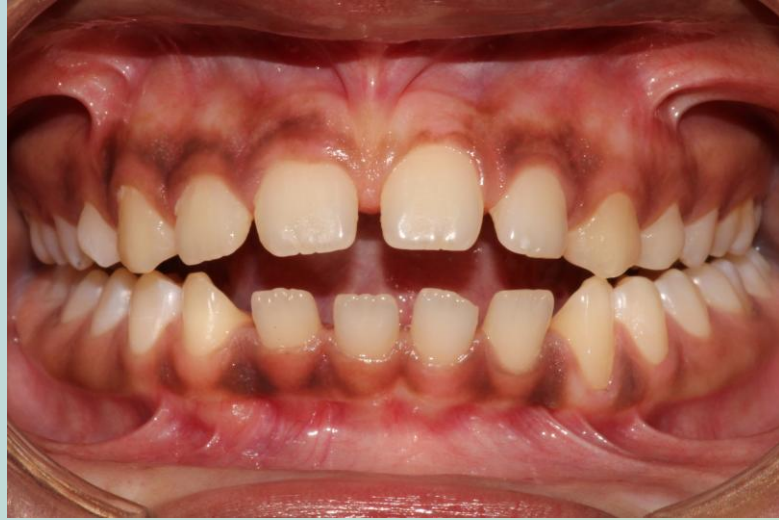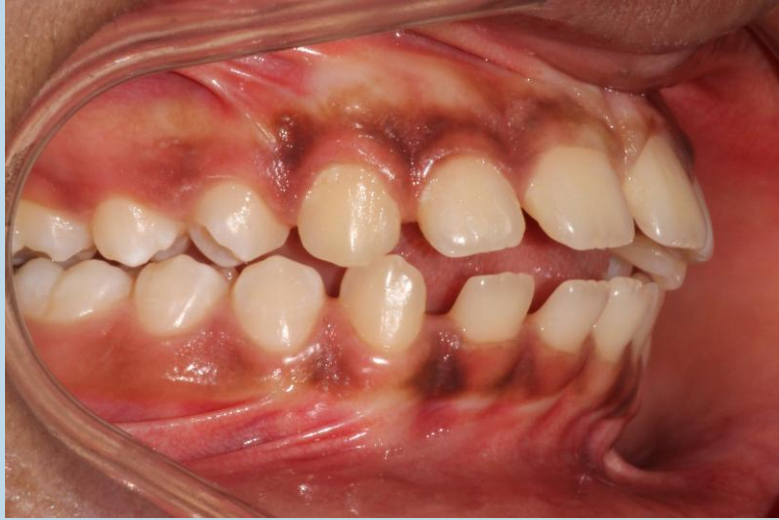Post - treatment Intraoral
Photographs



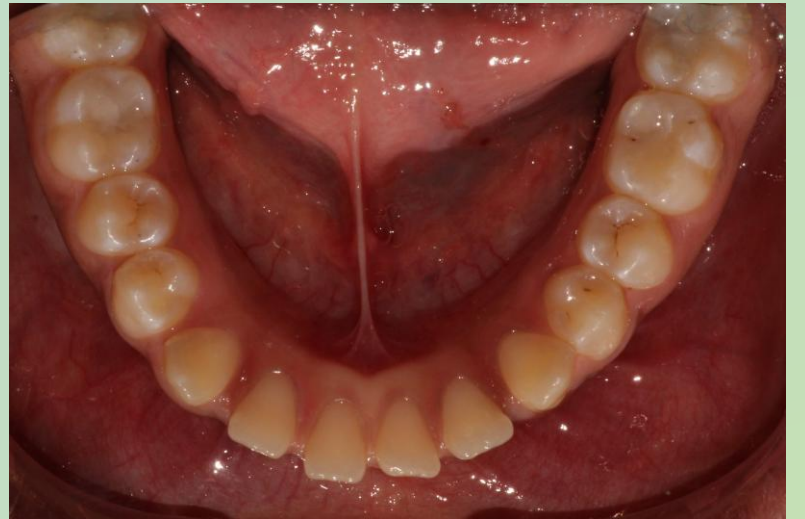Mini Brackets – Generalized Microdontia

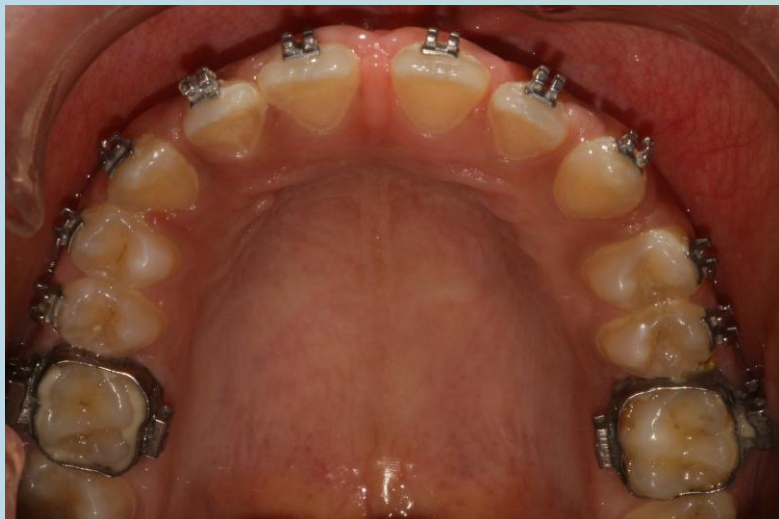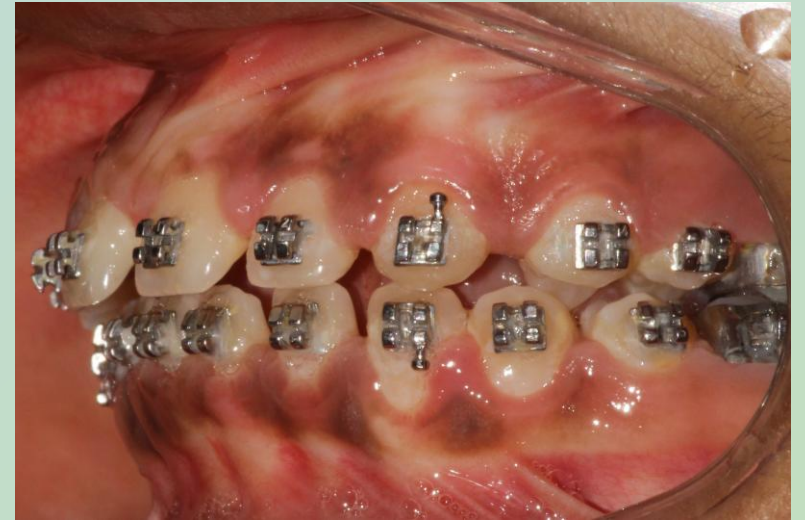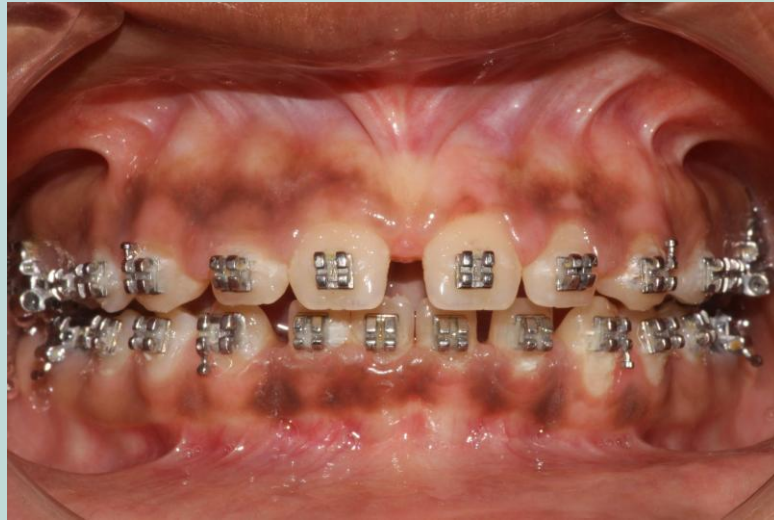


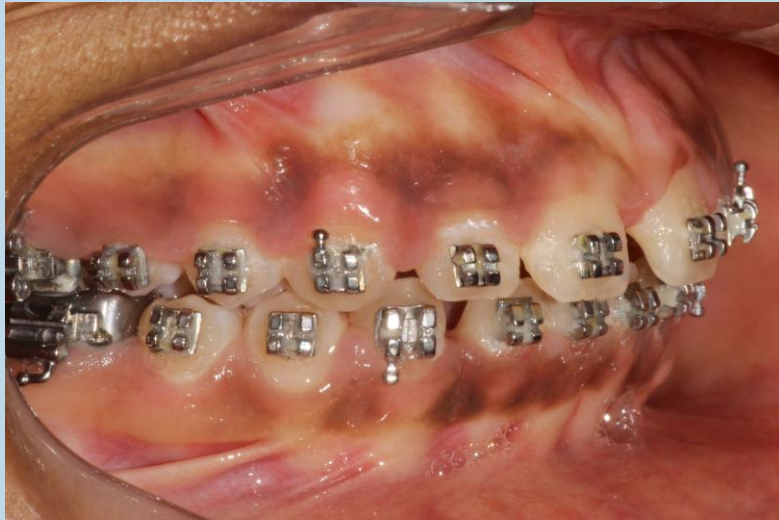Pre - treatment Extraoral Photographs

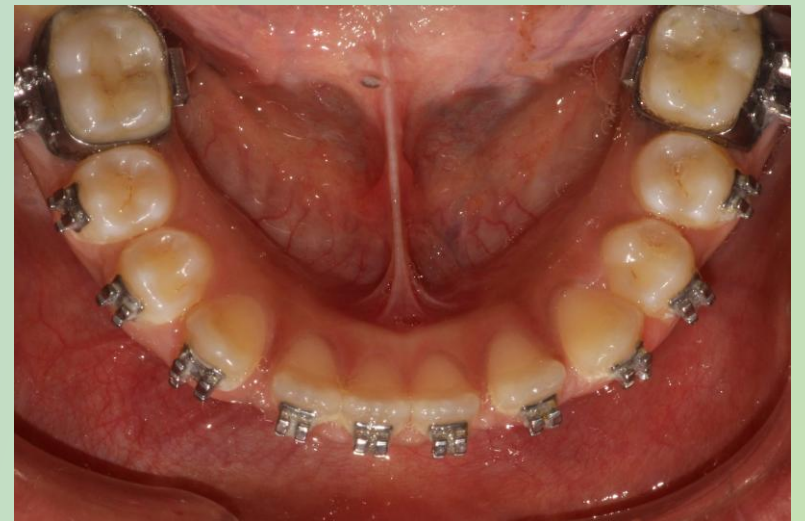



Pre - treatment Intraoral
Photographs



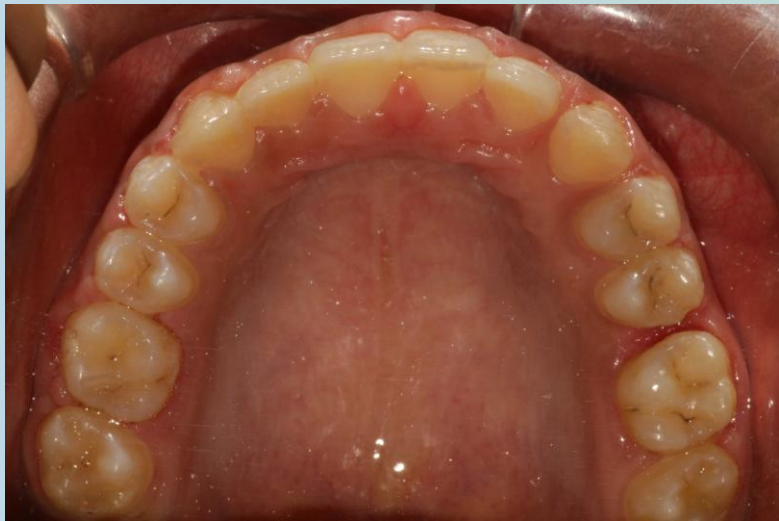
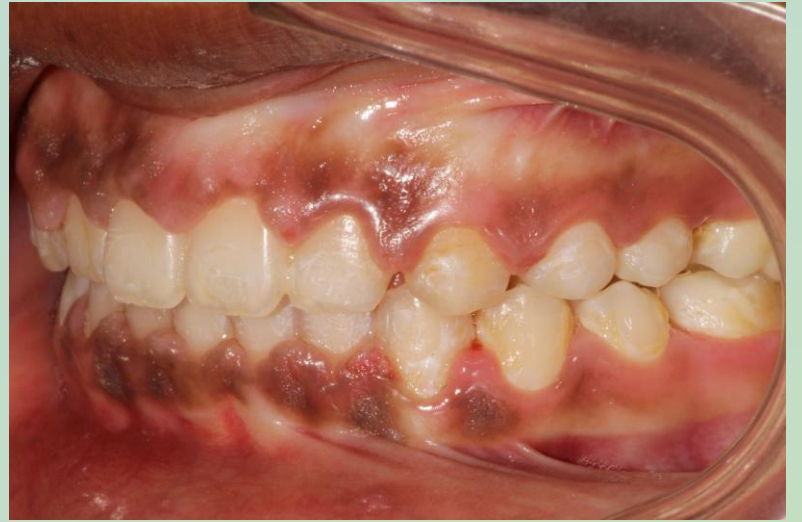
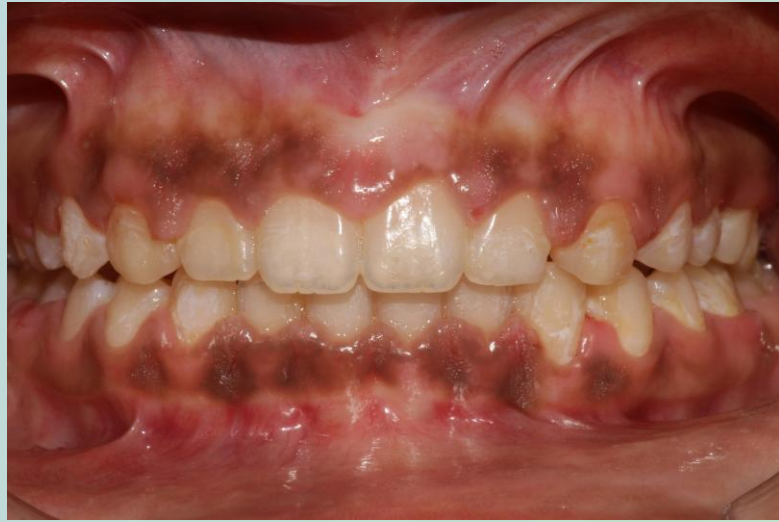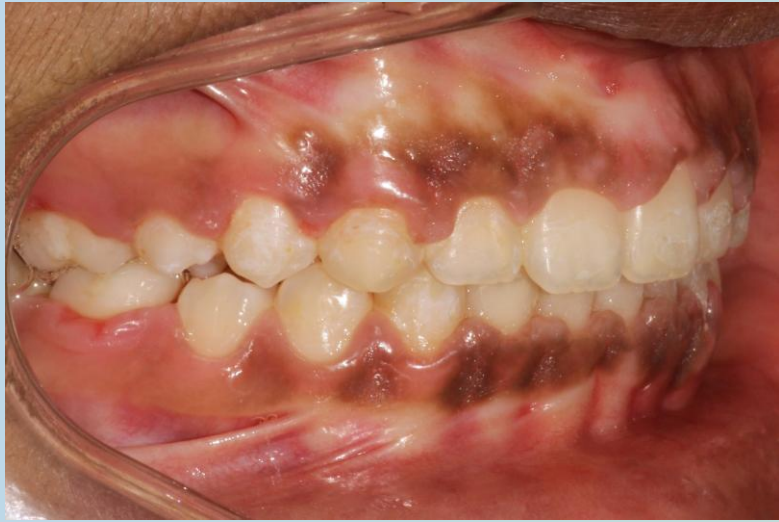Leveling and Aligning
Intraoral Photographs

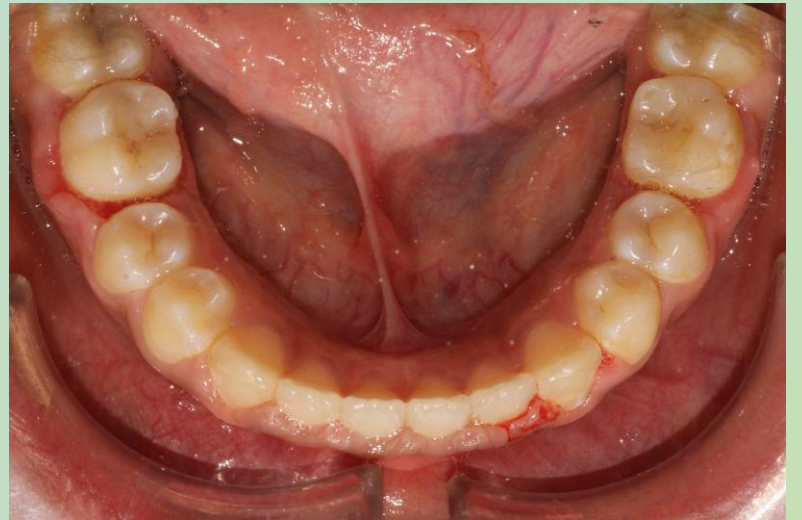



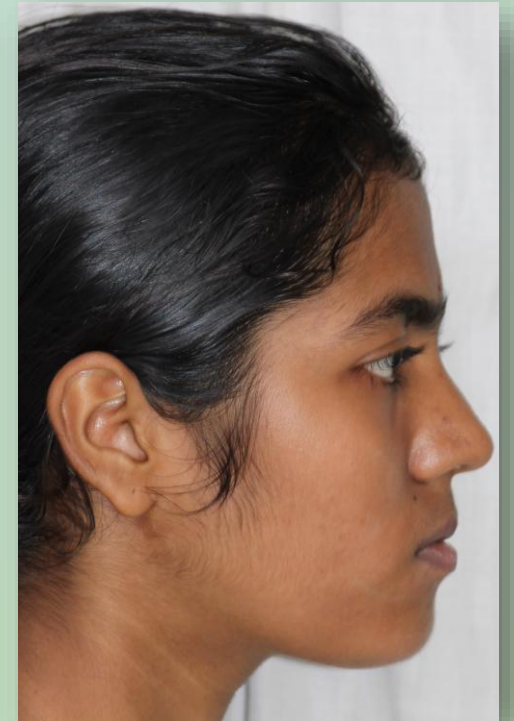

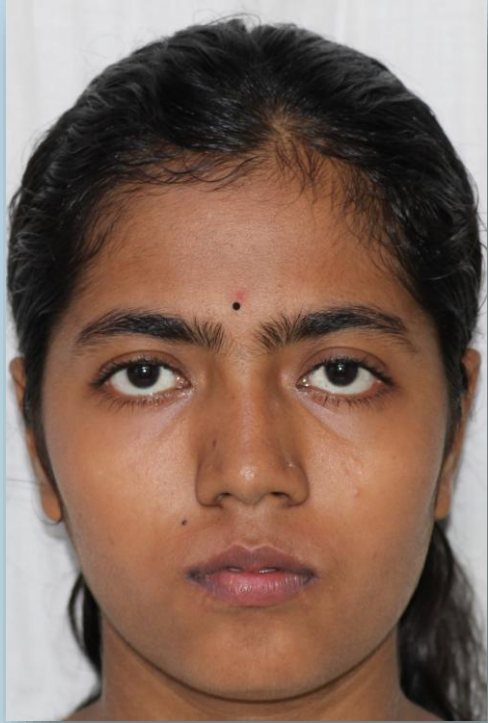Post - treatment Extraoral Photographs



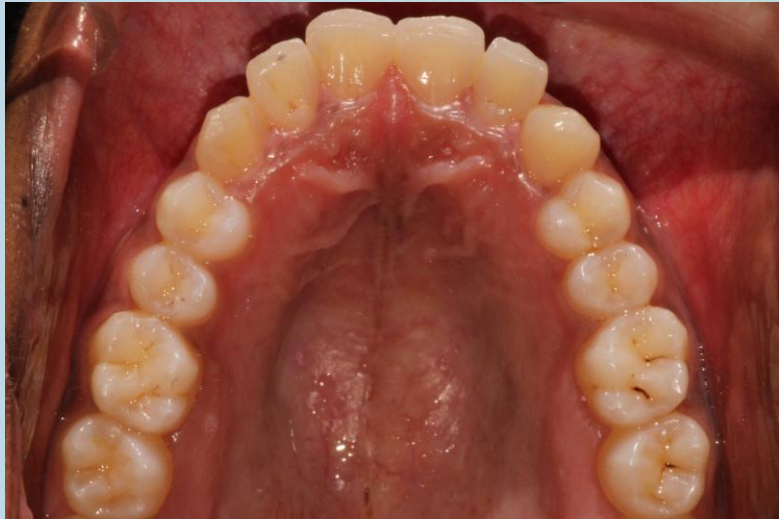
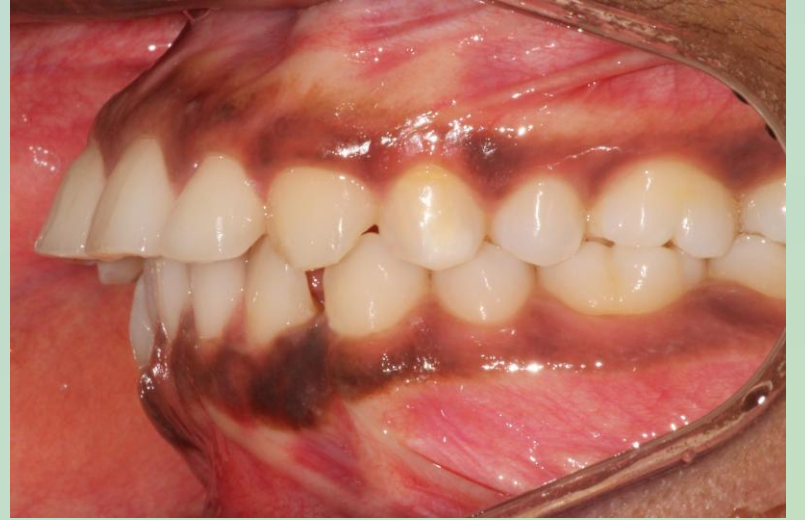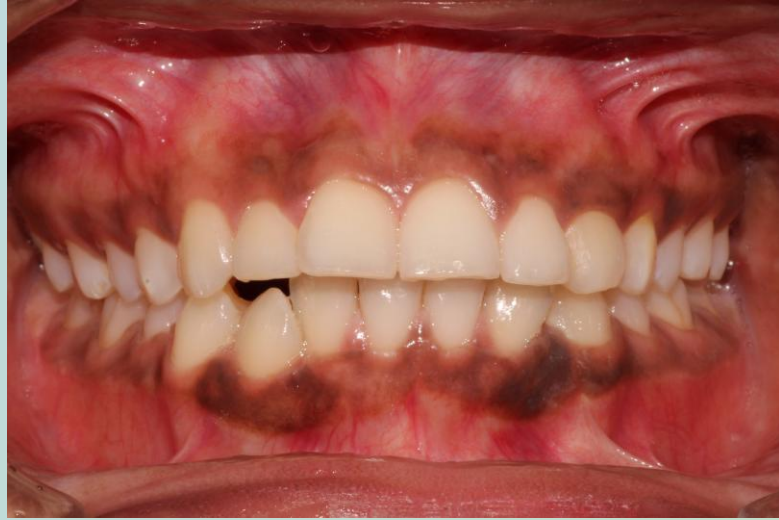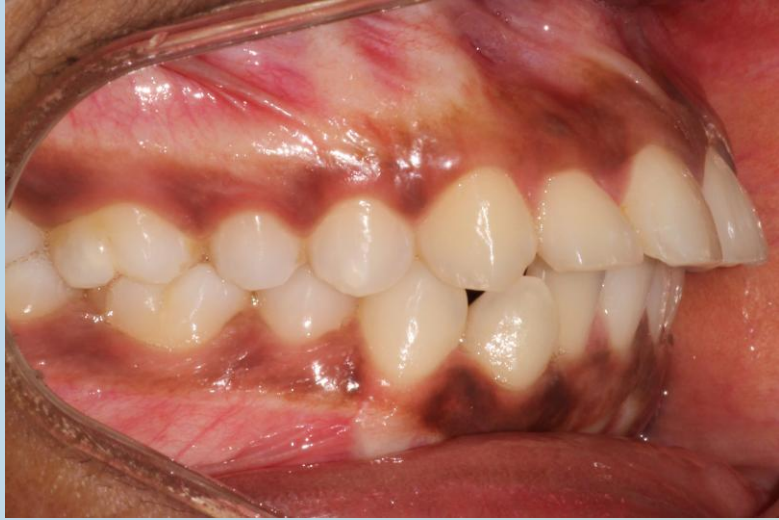Post - treatment Intraoral
Photographs



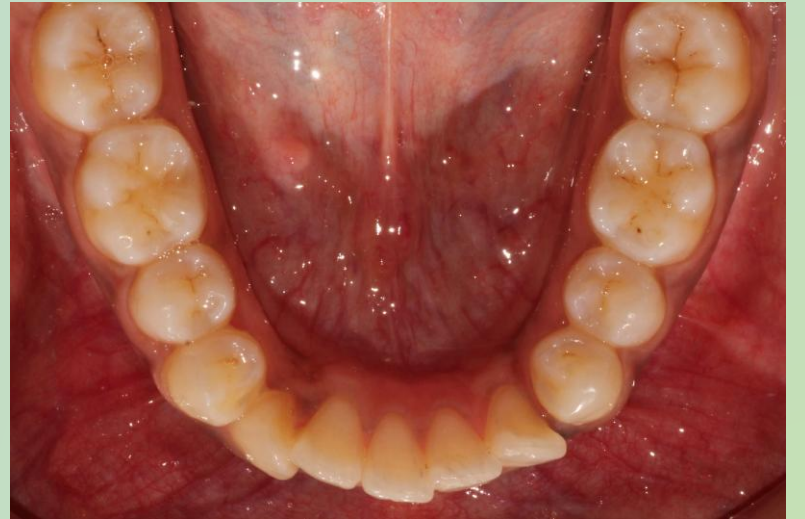Correction of mildly proclined teeth

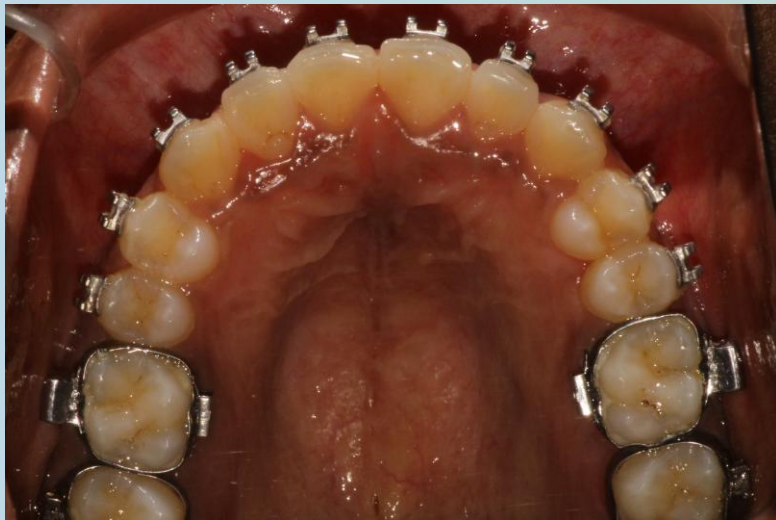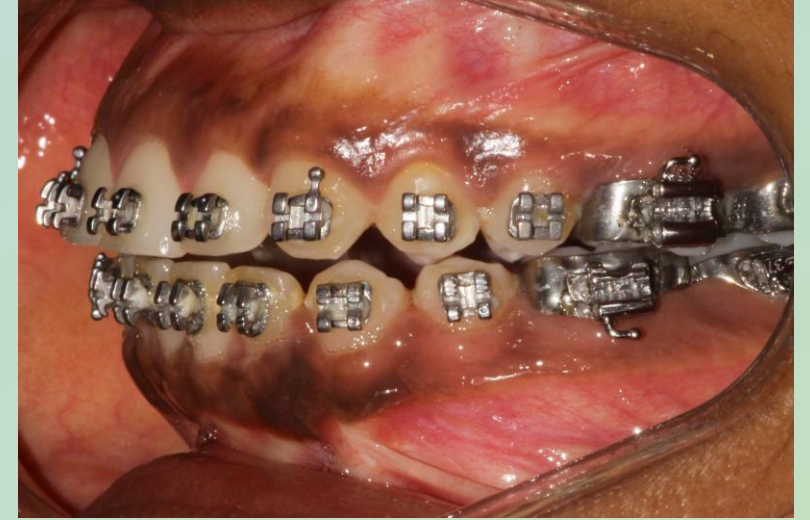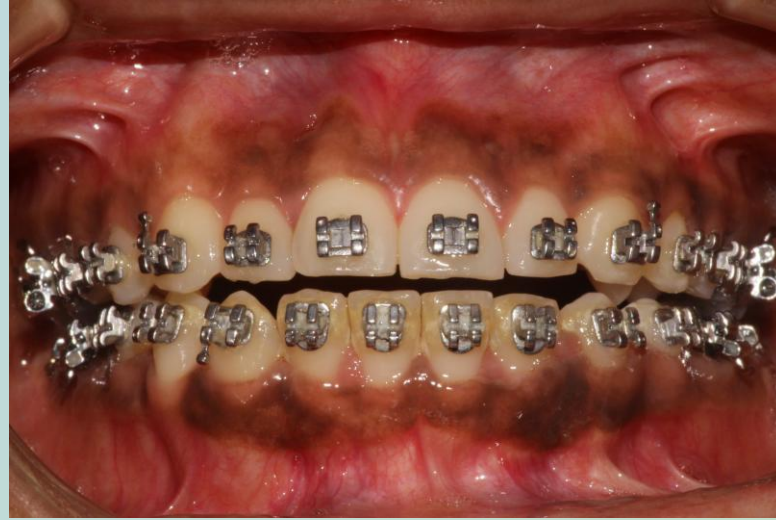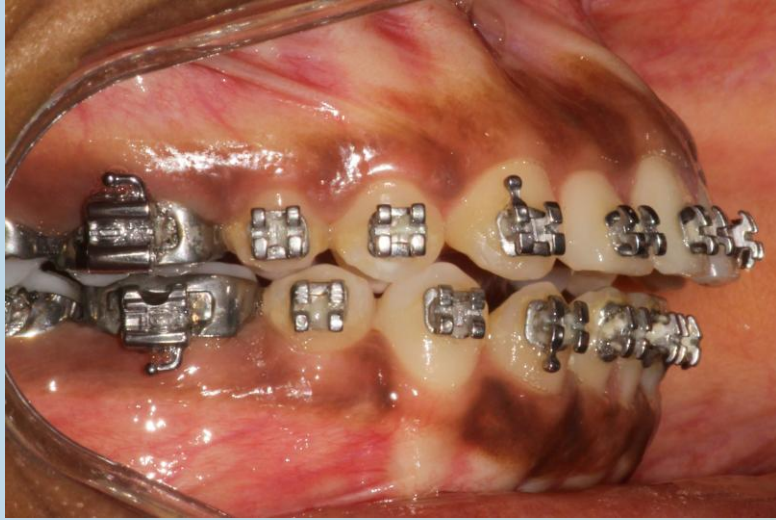


Pre - treatment Extraoral Photographs

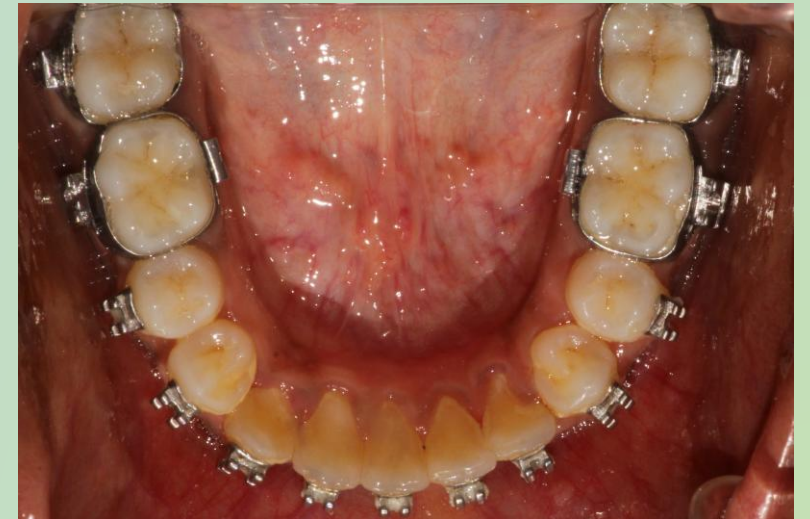

Pre - treatment Intraoral
Photographs



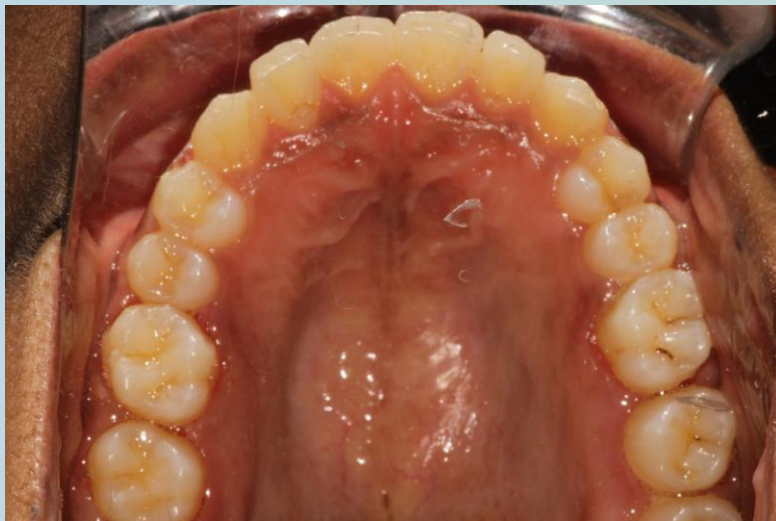
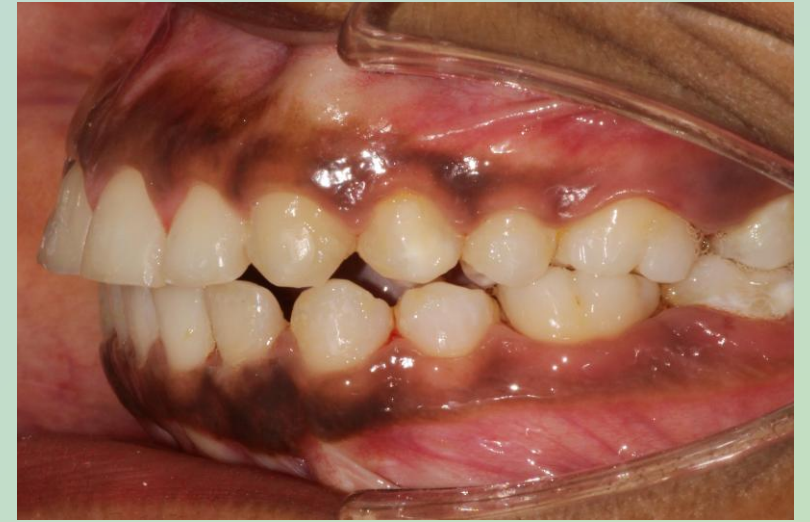
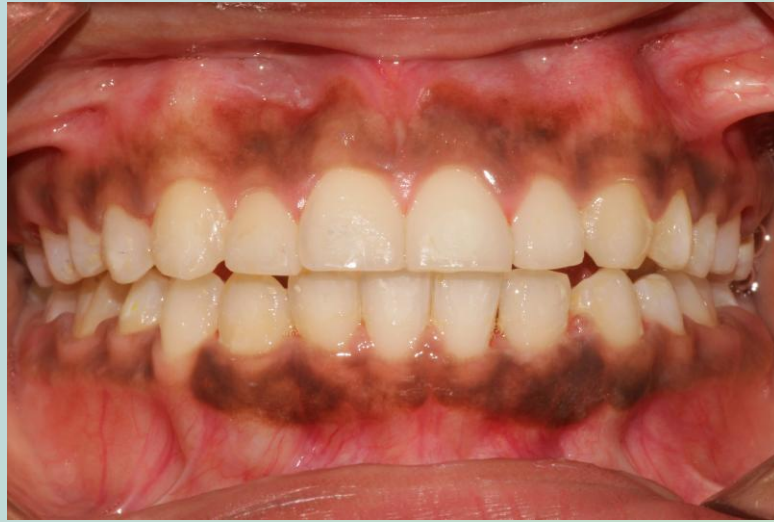
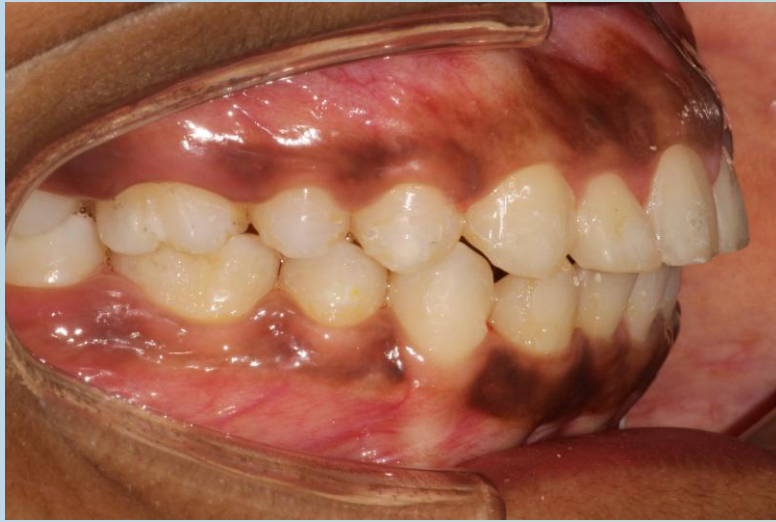Leveling and Aligning
Intraoral Photographs

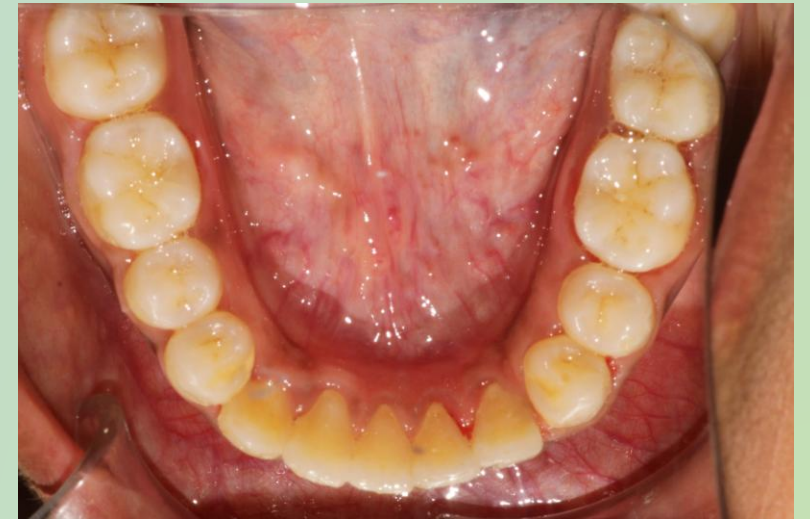





Post - treatment Extraoral Photographs



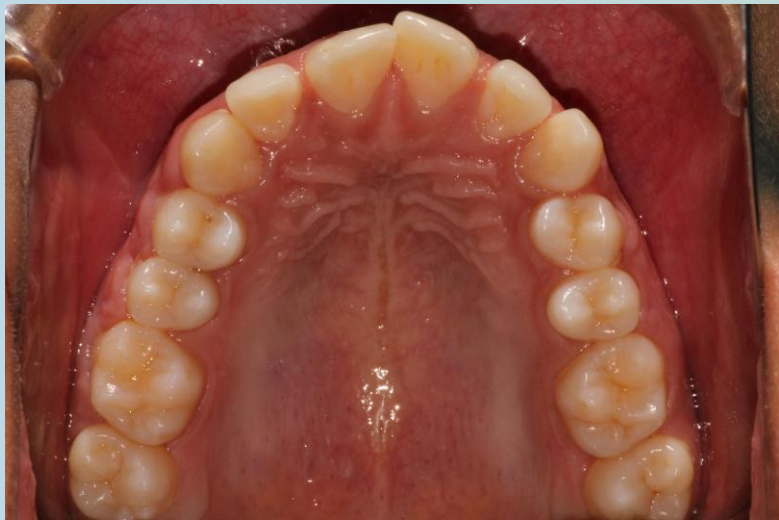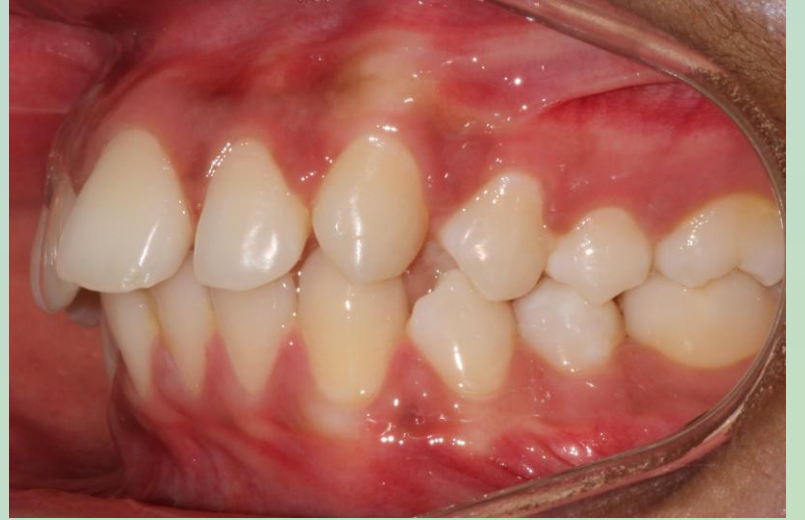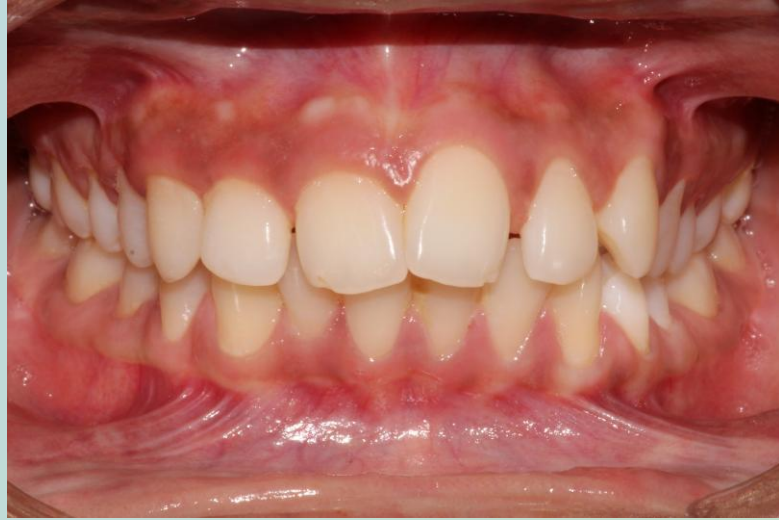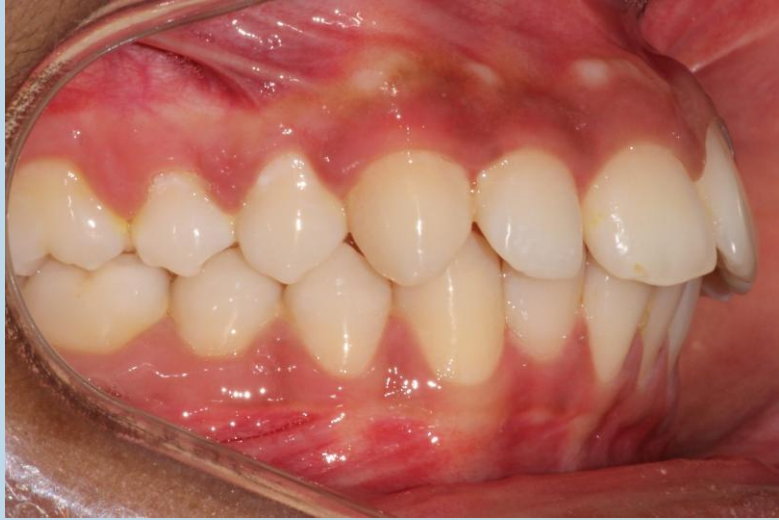Post - treatment Intraoral
Photographs



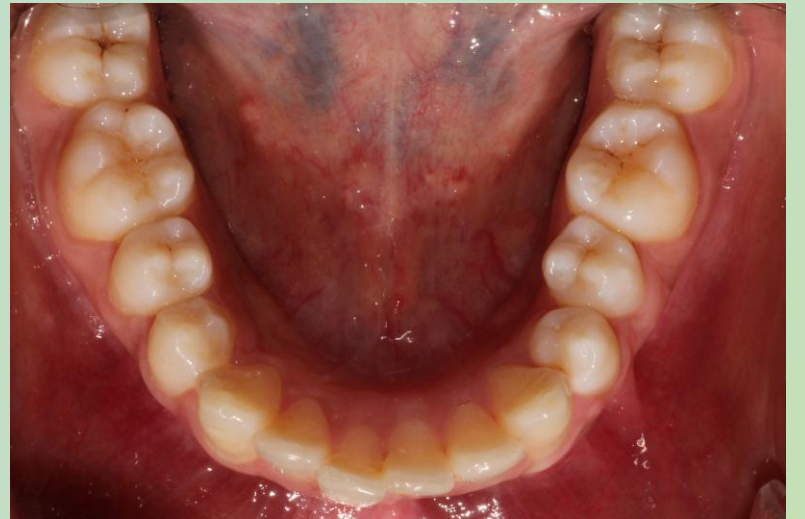Correction of minor crowding and spacing

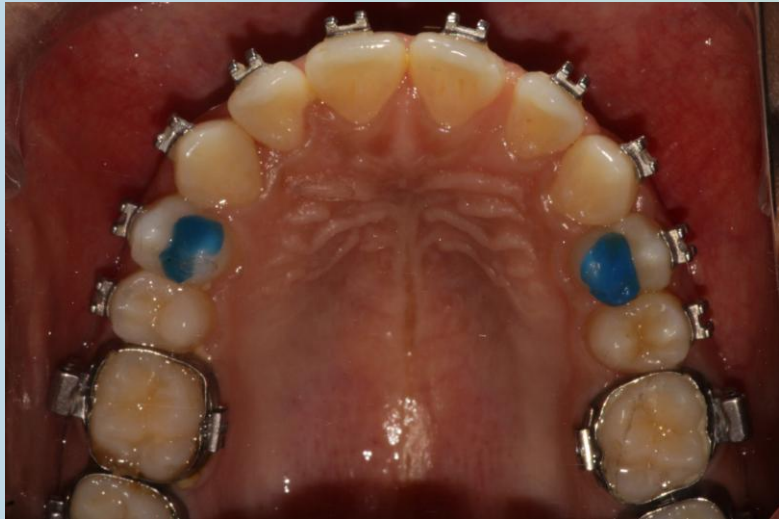
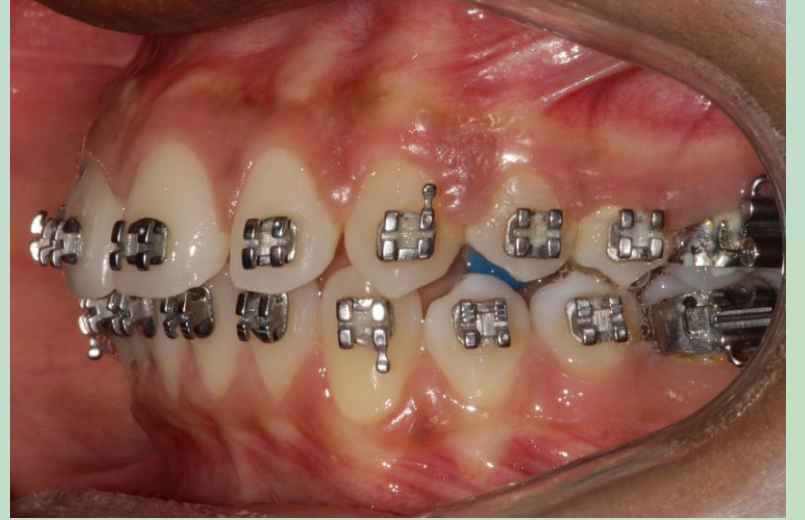
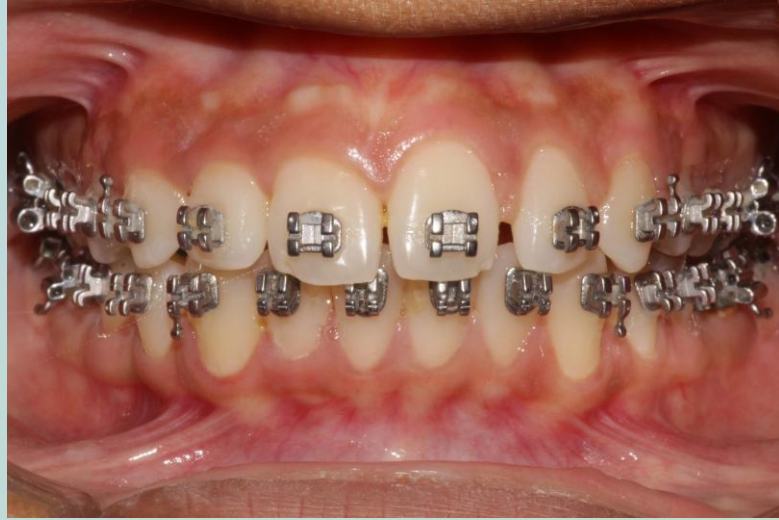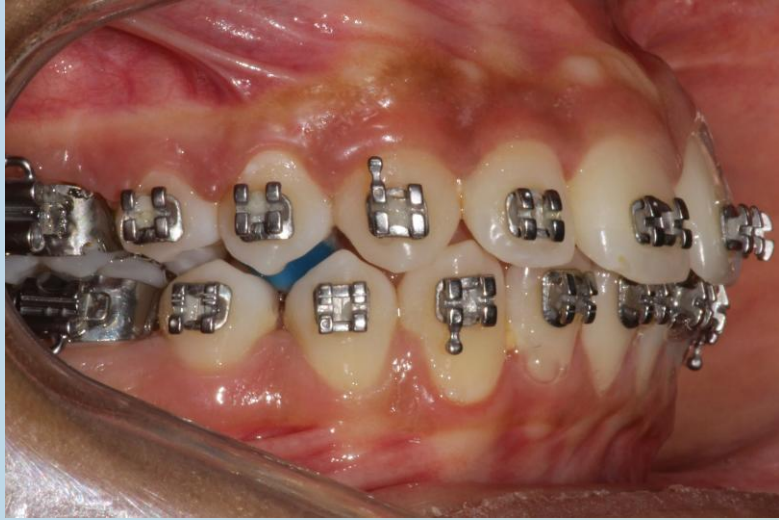Pre - treatment Extraoral Photographs

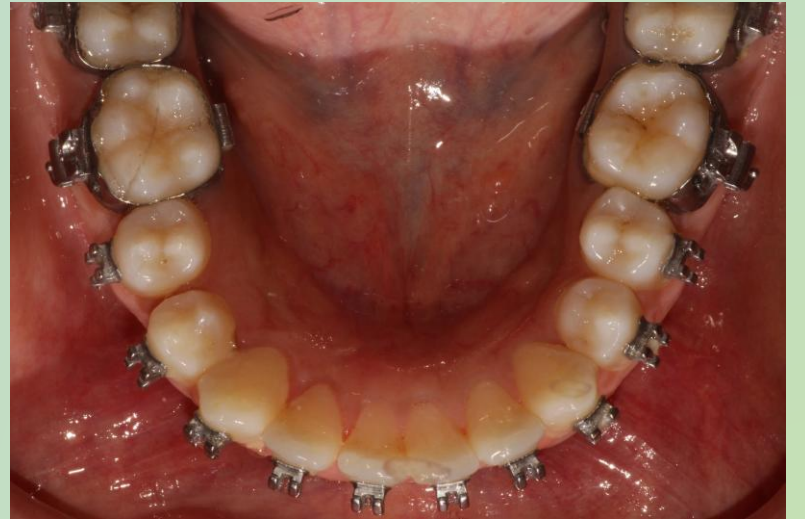


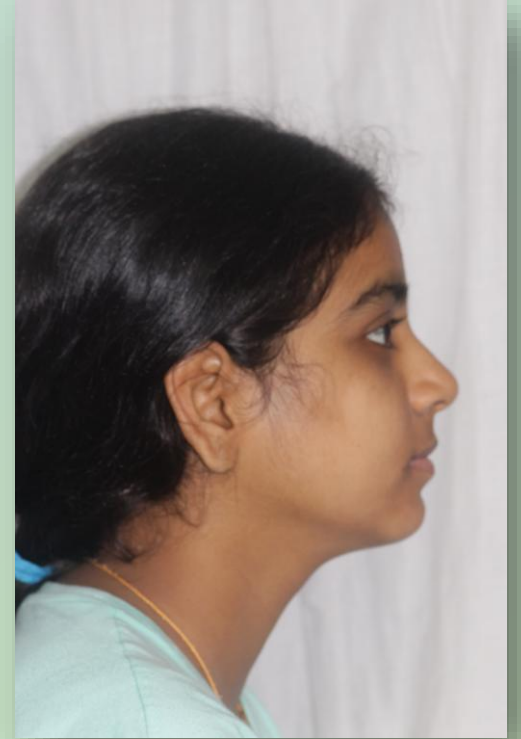Pre - treatment Intraoral
Photographs



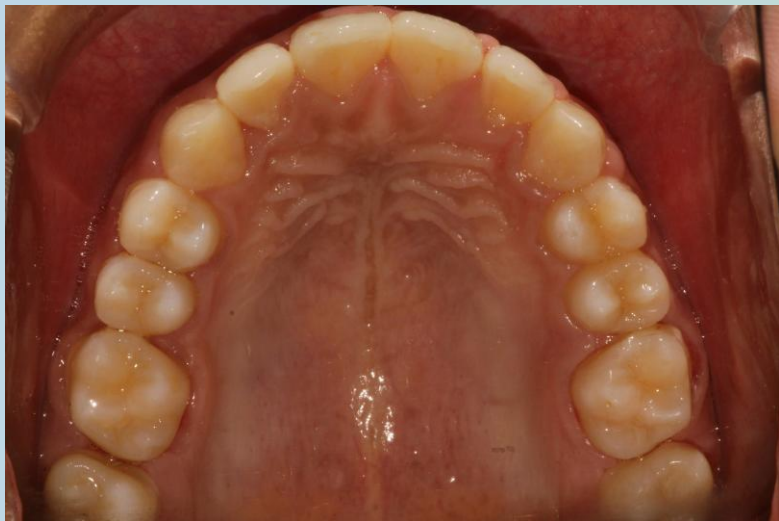
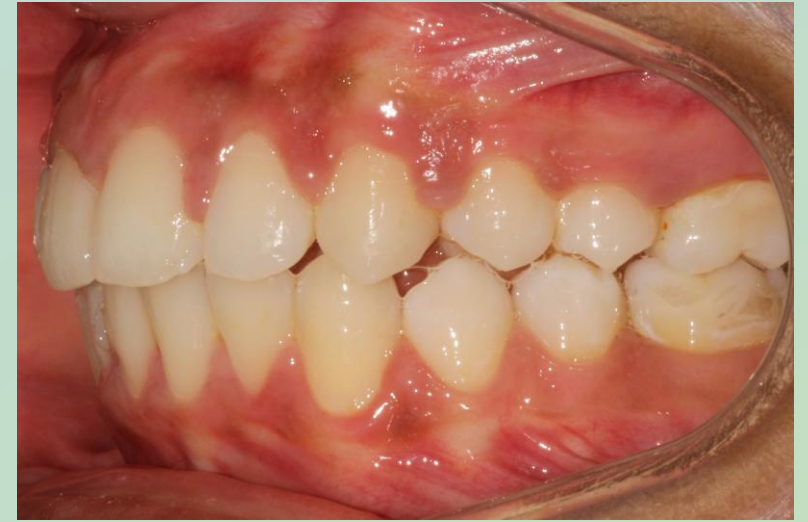
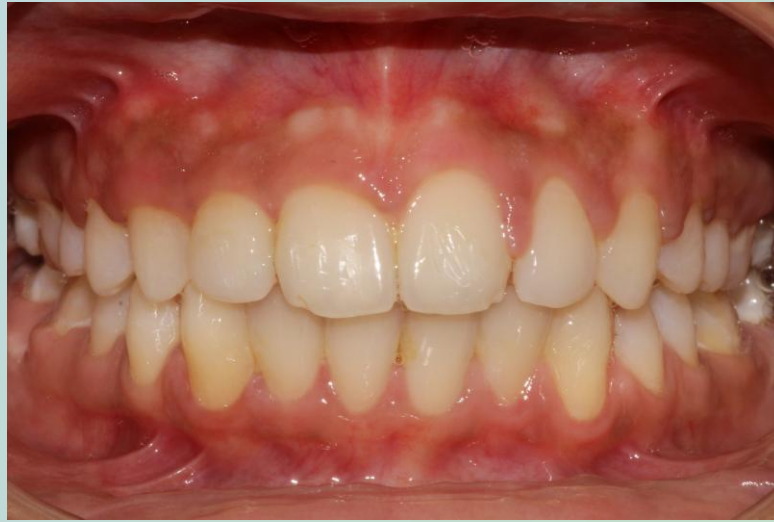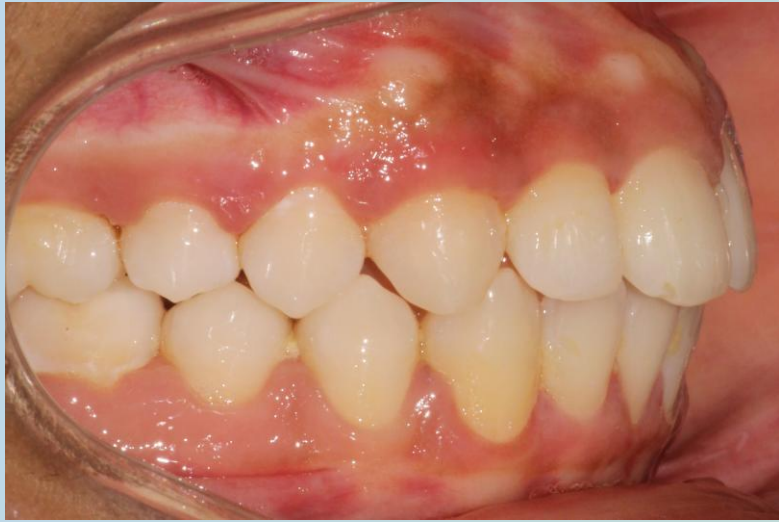Leveling and Aligning
Intraoral Photographs

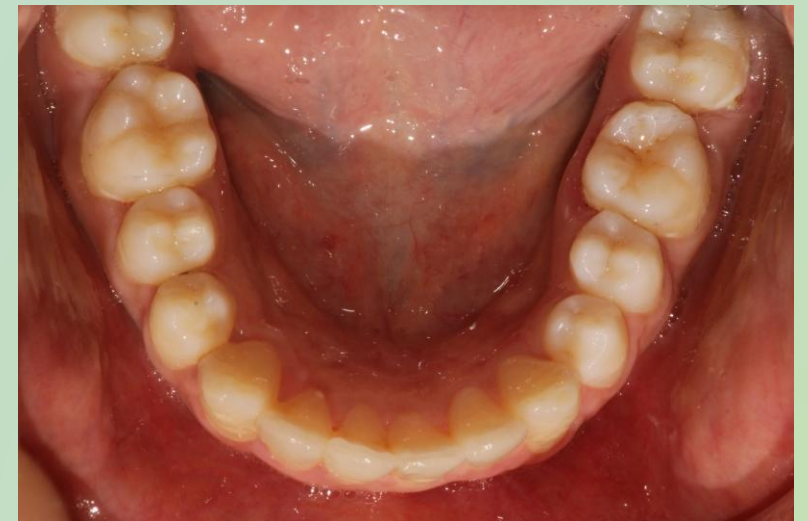



Post - treatment Extraoral Photographs



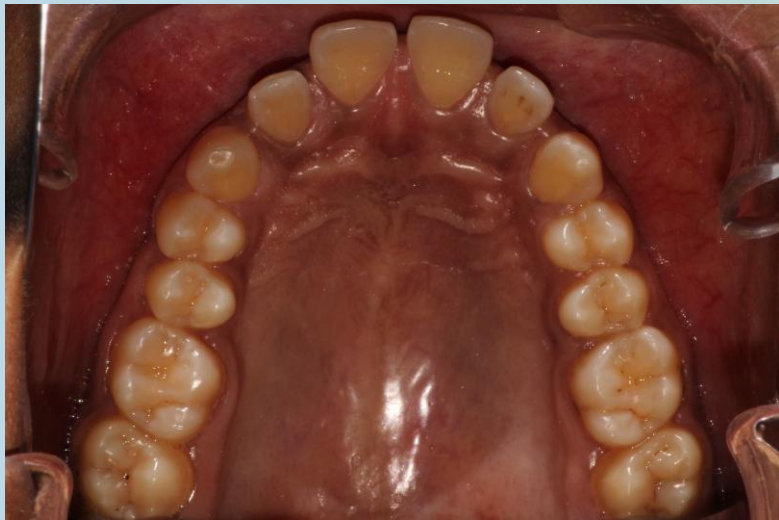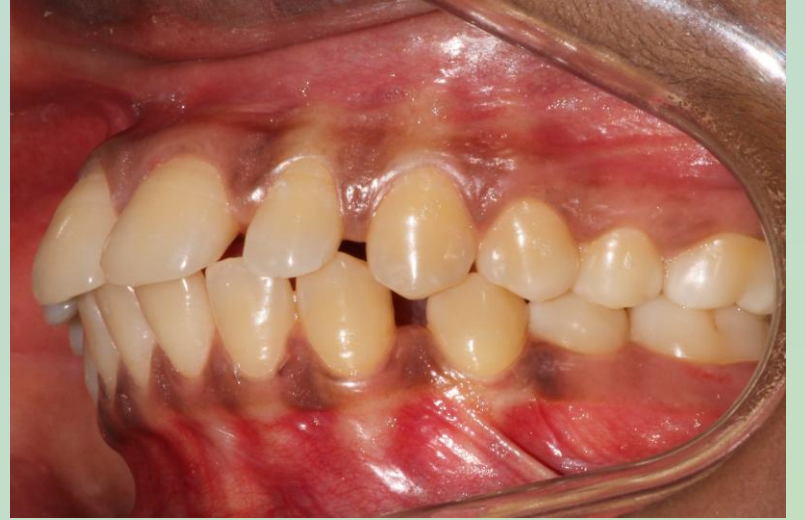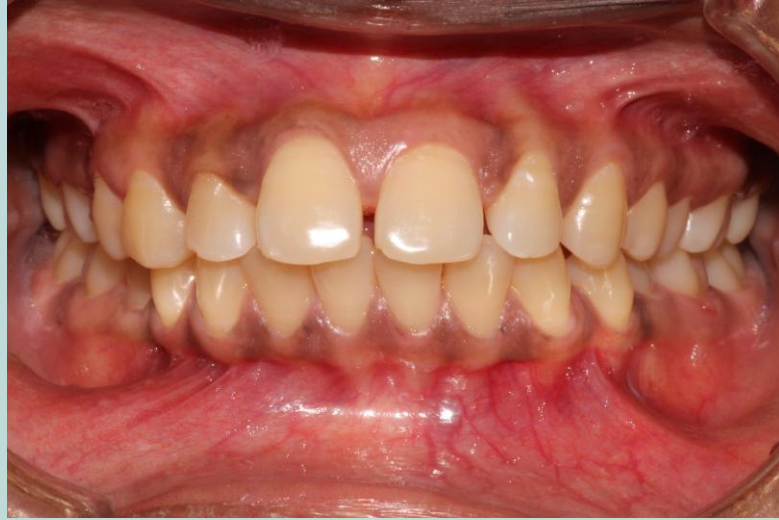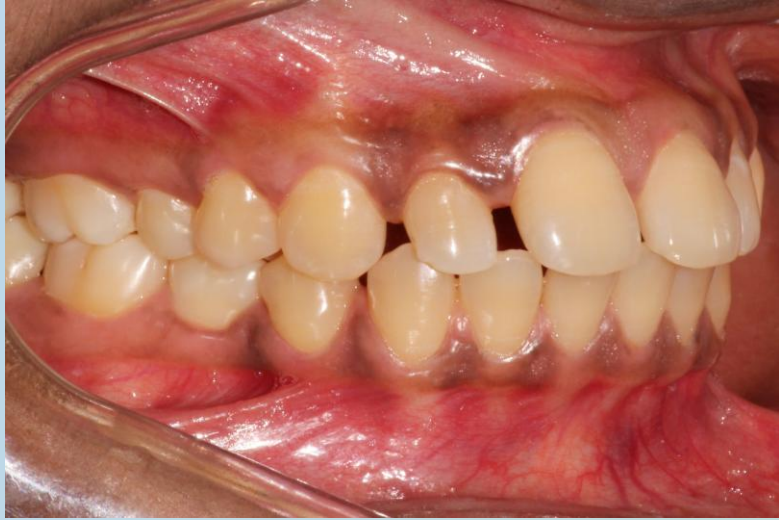Post - treatment Intraoral
Photographs



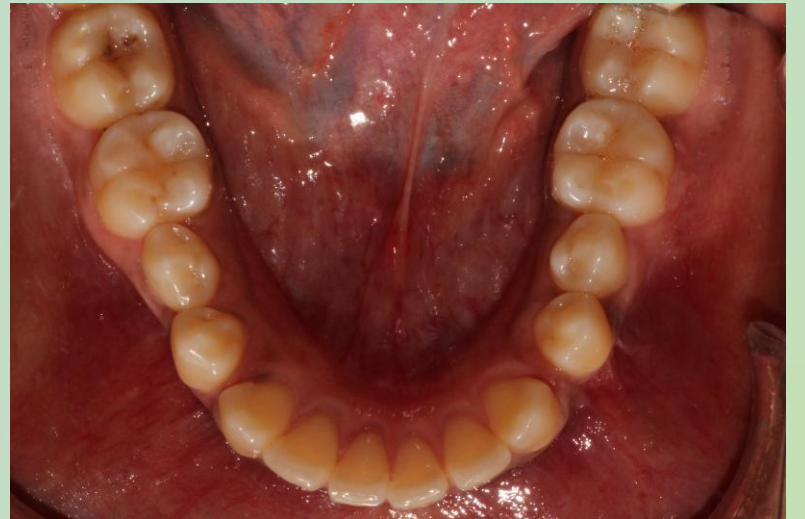
Correction of minor spacing

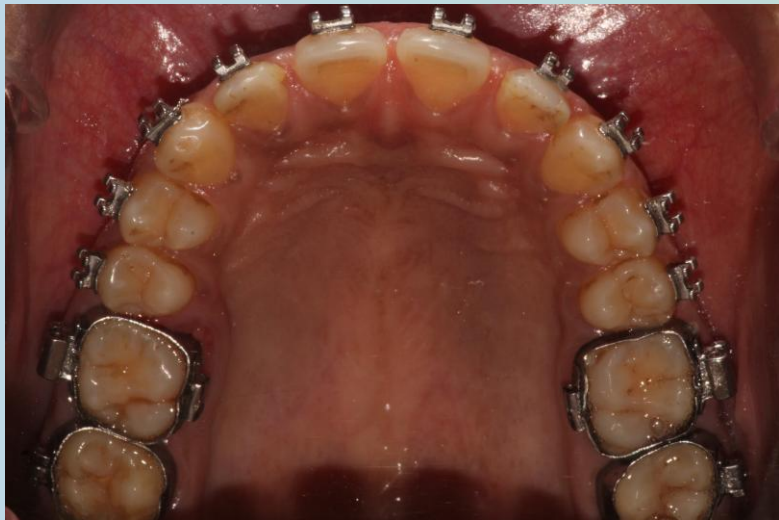
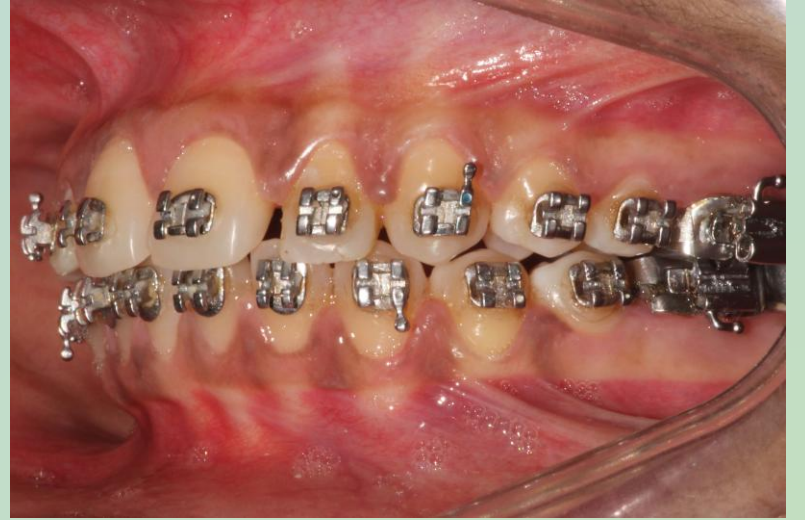
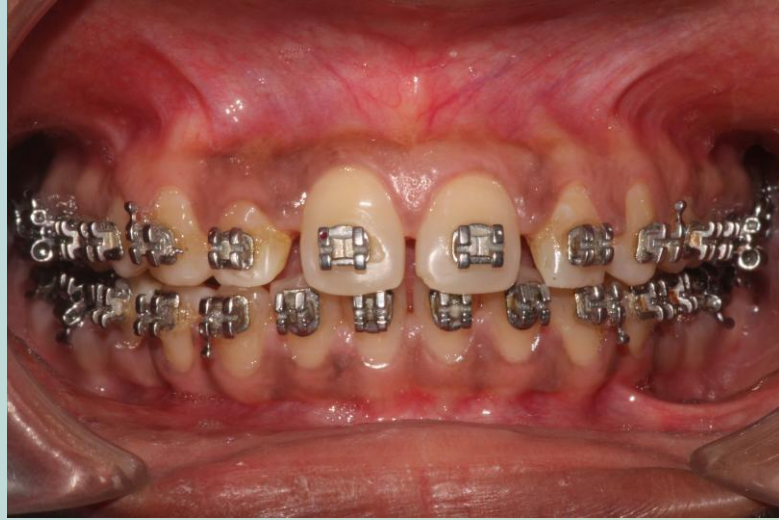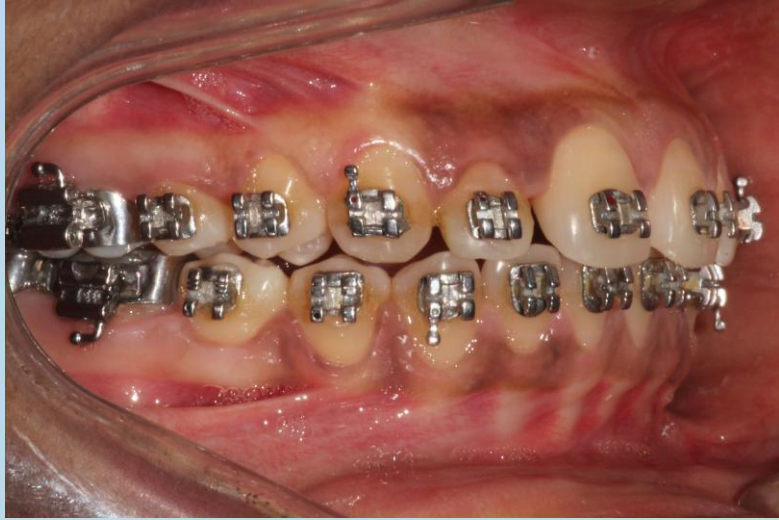Pre - treatment Extraoral Photographs

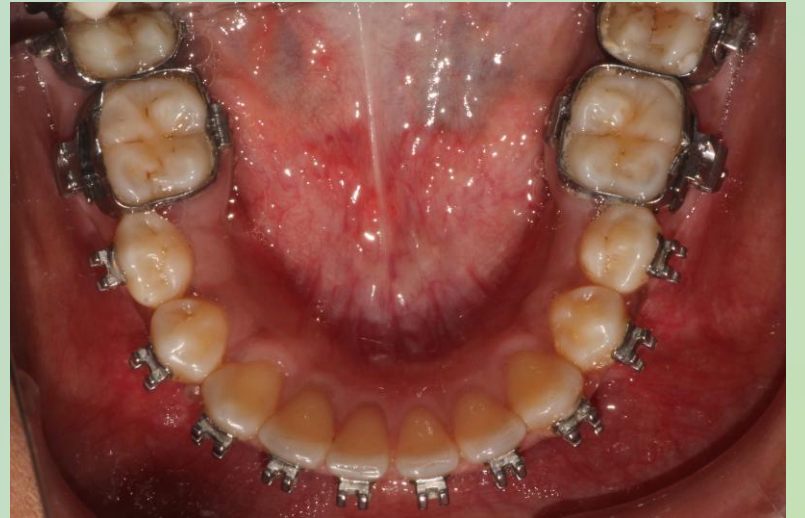

Pre - treatment Intraoral
Photographs



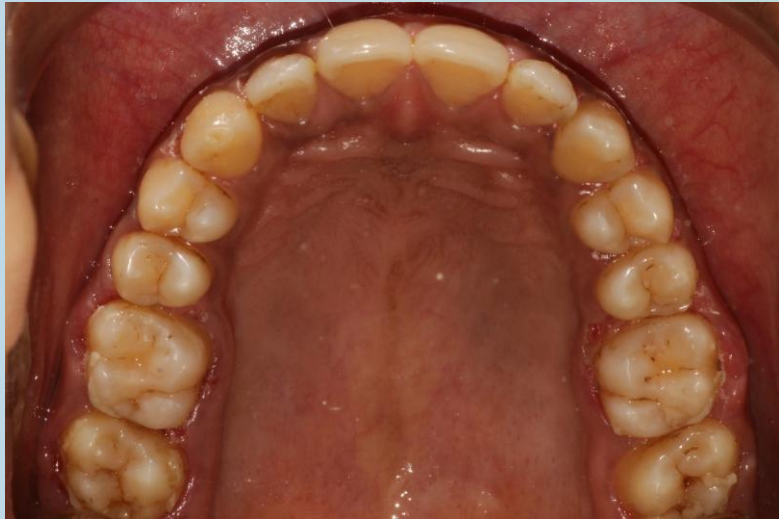
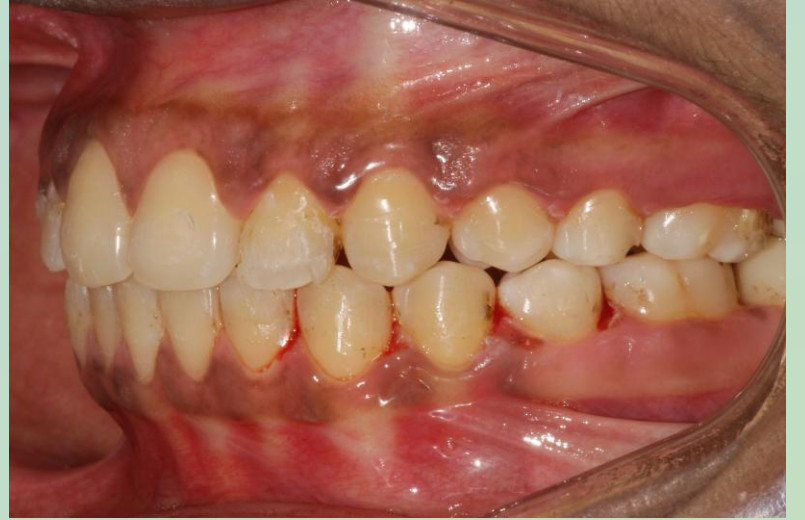
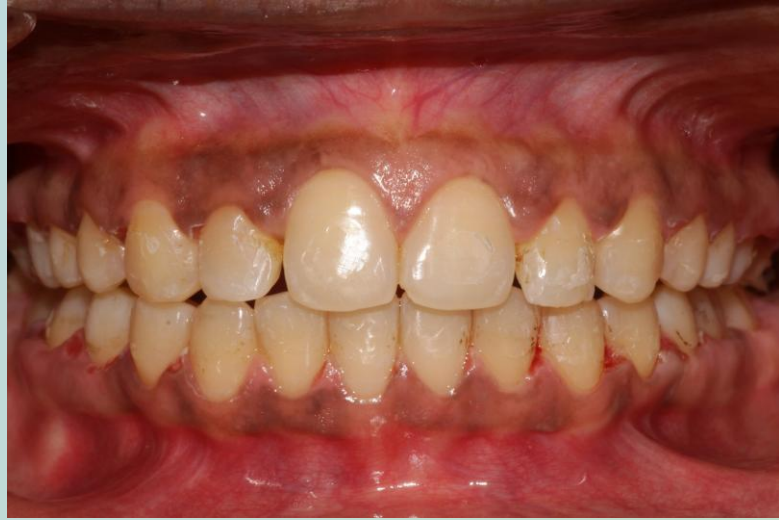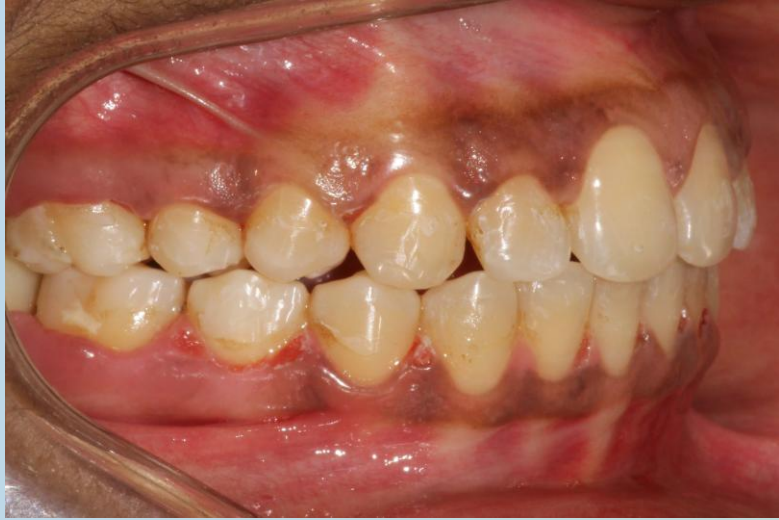Leveling and Aligning
Intraoral Photographs

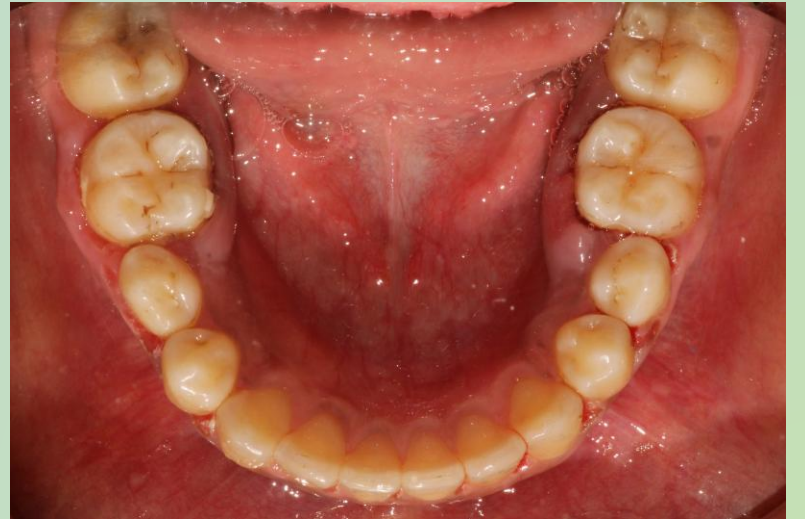



Post - treatment Extraoral Photographs



Post - treatment Intraoral
Photographs



THANK YOU!!!